NOYES KNEE INSTITUTE

KNEE ARTHROFIBROSIS: EVERYTHING YOU NEED TO KNOW TO RECOGNIZE, TREAT, AND PREVENT LOSS OF KNEE MOTION AFTER INJURY OR SURGERY

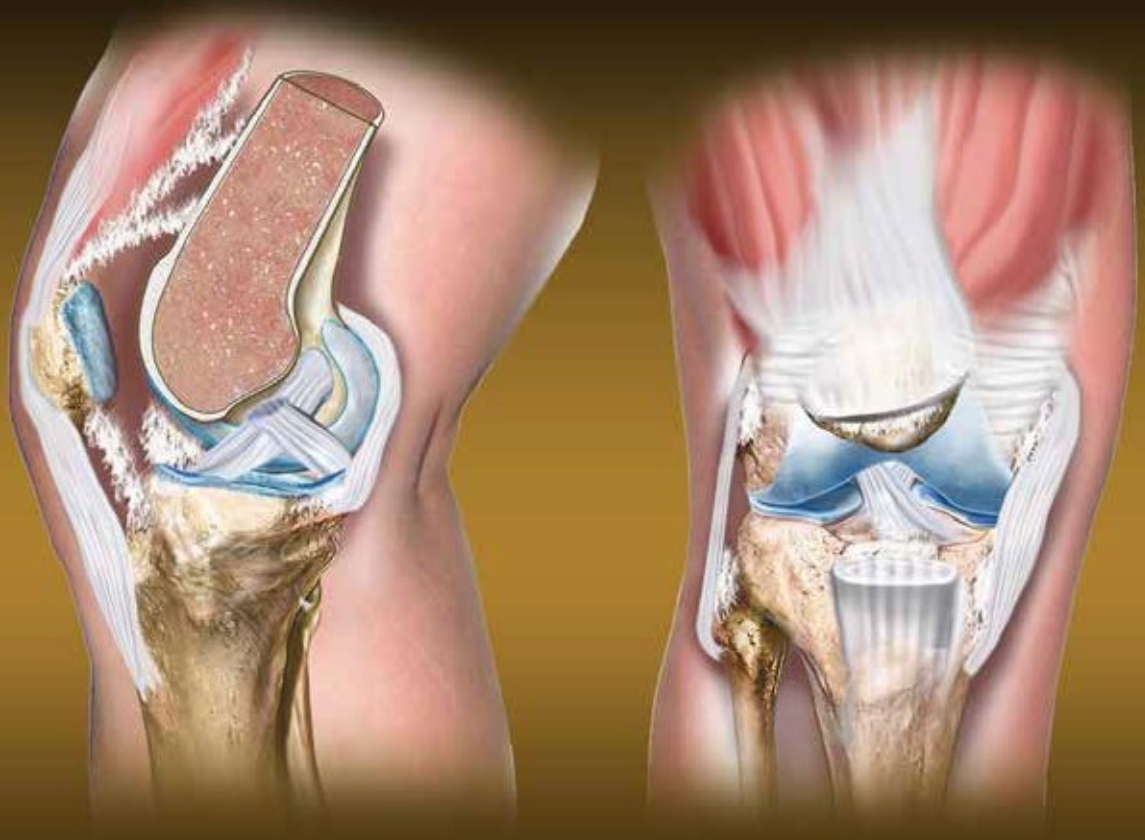

FRANK R. NOYES, M.D. AND SUE BARBER-WESTIN, B.S.
WRITTEN BY AN INTERNATIONALLY RECOGNIZED ORTHOPAEDIC SURGEON AND A CLINICAL RESEARCHER WITH DECADES OF EXPERIENCE IN TREATING PATIENTS WITH KNEE PROBLEMS

Table of Contents

About the Authors

Dr. Frank Noyes is an internationally recognized orthopaedic surgeon and researcher who has specialized in the treatment of knee injuries and disorders for nearly 4 decades. He is the founder and chairman of the Cincinnati SportsMedicine and Orthopaedic Center and its nonprofit research foundation. Dr. Noyes completed his orthopaedic training at the University of Michigan Medical Center. He then received a 4-year clinical and research appointment as an orthopaedic surgeon in the United States Air Force, was commissioned as a Lieutenant Colonel, and began his landmark research into knee ligament injuries, the effects of immobilization, biomechanics of ligaments, prevention of ACL injuries in the female athlete, the diagnosis of many knee injuries and problems, and the results of treatment for a variety of knee disorders. Along with Dr. Edward Grood, Dr. Noyes established one of the first biomechanics laboratories in the United States at the University of Cincinnati College of Engineering. A portion of the laboratory was subsequently named in his honor as the Noyes Tissue Engineering and Biomechanics Laboratory.

Dr. Noyes has won every conceivable award for his clinical and laboratory research from societies such as the American Academy of Orthopaedic Surgeons, the American Orthopaedic Society of Sports Medicine, the Orthopaedic Research and Education Foundation, as well as the University of Cincinnati. He was inducted into the American Orthopaedic Society for Sports Medicine's Hall of Fame in 2008. Dr. Noyes has been selected by his peers as one of the Best Doctors in America every year since 1992.

Dr. Noyes has published over 260 research studies and textbook chapters on many different types of knee injuries and disorders. He edited a textbook entitled, "Noyes' Knee Disorders: Surgery, Rehabilitation, Clinical Outcomes" which was written for orthopaedic surgeons, physical therapists, and other sports medicine health care professionals. Dr. Noyes is also a co-editor of "ACL Injuries in the Female Athlete. Causes, Impacts, and Conditioning Programs", a textbook written for sports medicine health care professionals, coaches, and trainers involved with female athletes.

Sue Barber-Westin has directed clinical research studies for Dr. Noyes' research Foundation for nearly 3 decades. In the mid 1980's, she authored one of the first studies that measured problems during single-leg hopping tests in patients with ACL injuries, "Quantitative Assessment of Functional Limitations in Normal and Anterior Cruciate Ligament-Deficient Knees." She has co-authored 140 articles in medical journals and textbooks, focusing on the clinical outcome of various knee operative procedures, the methods used to determine the results of clinical investigations, differences in neuromuscular indices between male and female athletes, effects of neuromuscular training in female athletes, and prevention of ACL injuries in female athletes. Sue is the associate editor of "Knee Disorders: Surgery, Rehabilitation, Clinical Outcomes" and is the co-editor for "ACL Injuries in the Female Athlete. Causes, Impacts, and Conditioning Programs". Sue has personally undergone 4 knee operations and played competitive junior and collegiate tennis.

In 2004, Sue and Dr. Noyes were members of the research team that won the Clinical Research Award from the Orthopaedic Research and Education Foundation. They are frequently invited to speak at national and international conferences and review articles for orthopaedic and sports medicine journals. Noyes and Barber-Westin have written other eBooks for patients:

- ACL Injury: Everything You Need to Know to Make the Right Treatment Decision
- ACL Injury Rehabilitation: Everything You Need to Know to Restore Knee Function and Return to Activity
- Knee Meniscus (Cartilage) Tears: Everything You Need to Know to Make the Right Treatment Decision
- Patellar (Kneecap) Pain and Problems: Everything You Need to Know to Make the Right Treatment Decision
- Operations for Knee Arthritis: What to do When All Else Has Failed to Stop Your Knee Pain

Introduction

Arthrofibrosis is a term that may be broken down to "arthr" meaning joint and "fibrosis" meaning scarring. In short, arthrofibrosis indicates excessive scarring that limits a joint's normal amount of movement. This problem may happen in any joint in the body (wrist, shoulder, ankle, knee). Fibrosis, or excessive scarring, may also occur in the organs (lungs, liver, heart) and in other areas such as the intestine, skin, and bone marrow.

Arthrofibrosis occurs as a part of the body's healing process after an injury or operation. For reasons scientists are still trying to understand, in some people, the body's response is greatly exaggerated and an excessive amount of scar tissue is produced. In the knee, this results in a limitation of the normal amount of flexion (how far the knee bends) and extension (how far the knee straightens). If untreated, arthrofibrosis eventually causes permanent dysfunction of the limb and severe arthritis.

There are many conditions or factors that may cause arthrofibrosis. These include a serious injury to the knee (fracture or dislocation), an infection, an operation that has been done incorrectly, poor or non-existent physical therapy, and so on. Arthrofibrosis triggered by these conditions or problems is referred to as secondary arthrofibrosis because the scarring is a local problem that occurred from a specific cause and is not part of a generalized healing disorder. The vast majority of patients treated for arthrofibrosis are in this category. However, in rare cases, arthrofibrosis occurs without an inciting event in patients who have a general problem with scar tissue biology, and who tend to normally produce excessive scar tissue in response to any injury or surgery anywhere in the body. This problem is referred to as primary arthrofibrosis.

Although we focus on knee arthrofibrosis in this eBook, information gained from the detection, pathophysiology, and treatment of fibrosis in other parts of the body is used in certain sections. The content you will read stems from our personal experience in treating patients for many years with this problem, our extensive clinical studies relating to a variety of knee operations and rehabilitation programs that have helped reduce or prevent the condition, and information from clinical studies from other orthopaedic centers regarding knee arthrofibrosis.

Fortunately, the incidence of knee arthrofibrosis has decreased over the course of the last few decades as clinicians have improved their ability to diagnose and prevent the full-blown disorder. For instance, one of the leading causes of loss of knee motion in the 1970's and 1980's was the use of casts for several weeks after certain types of knee operations such as anterior cruciate ligament (ACL) reconstruction and high tibial osteotomy (HTO). During this time period, ACL reconstruction was associated with incidences of arthrofibrosis as high as 19-35%. An unacceptably high incidence of arthrofibrosis was also reported after HTO. Currently, with improved understanding of this complication and changes in surgical timing and techniques and rehabilitation, the incidence of arthrofibrosis following ACL reconstruction is less than 10%. In our Center, a focus on immediate knee motion and early management of extension and flexion limitations after ACL reconstruction and HTO has resulted in a less than 1% incidence in studies conducted in over 700 patients.

Arthrofibrosis occurs in approximately 1-10% of patients who undergo total knee replacement. This complication has been reported in 1-20% of patients who have had an autologous chondrocyte implantation (ACI). The incidence may be even higher following trauma such as knee dislocations and fractures that require surgery and internal fixation. One study (Stephenson et al, 2010) estimated that the number of patients who undergo major knee surgery in the United States that are subsequently affected by arthrofibrosis is at least 85,000 a year. Of these, 21,000 are at risk of requiring additional operations and 54,000 may have an unsuccessful outcome of treatment for this complication.

Permanent arthrofibrosis is a disaster because patients suffering from this complication never have a knee that resembles normal. Trying to deal with arthrofibrosis is extremely time-consuming and affects all portions of a patient's life. In our experience, the majority of individuals sustained their original injury playing sports and were very active. The loss of the ability to participate even in low impact activities brings on depression and tremendous anxiety. In addition, most patients are young, in their 3rd to 4th decade of life, which is far too early to lose the ability to have an active lifestyle.

Similar problems occur after total knee replacement when arthrofibrosis develops. The patient may have faithfully followed the rehabilitation program and did everything asked of them. However, the excessive scar tissue causes pain with daily activities and the expected functional goals of returning to an active lifestyle are not achieved. Repeat surgery may or may not solve the problem.

Fortunately, knee arthrofibrosis can be prevented 80-90% of the time, which we will discuss in detail. This is because the majority of cases are secondary in nature. This complication is certainly easier to prevent than it is to treat, especially when it becomes a chronic condition. The early detection of excessive scarring leads to successful resolution in most (but not all) patients, provided the treatment is done correctly and the patient complies with the rehabilitation program.

This eBook provides information on basic knee anatomy, what knee structures may be affected in the arthrofibrosis process, how arthrofibrosis happens and how it is diagnosed, prevention of the problem, and conservative and operative treatment options. Two other serious medical issues that may either cause arthrofibrosis (complex regional pain syndrome) or occur as a result of arthrofibrosis (patella infera) are also discussed in detail.

This eBook should not be used for self-diagnosis and treatment of knee arthrofibrosis. Only a qualified orthopedist or sports medicine-trained physician can make a definitive diagnosis of this problem. For medical professionals, we recommend our textbook "Noyes' Knee Disorders. Surgery, Rehabilitation, Clinical Outcomes" for more comprehensive information regarding the diagnosis and treatment of knee arthrofibrosis, as well as other knee problems such as knee ligament tears, patellofemoral problems, preventing knee ligament injuries in the female athlete, meniscus injuries, and cartilage restoration procedures.

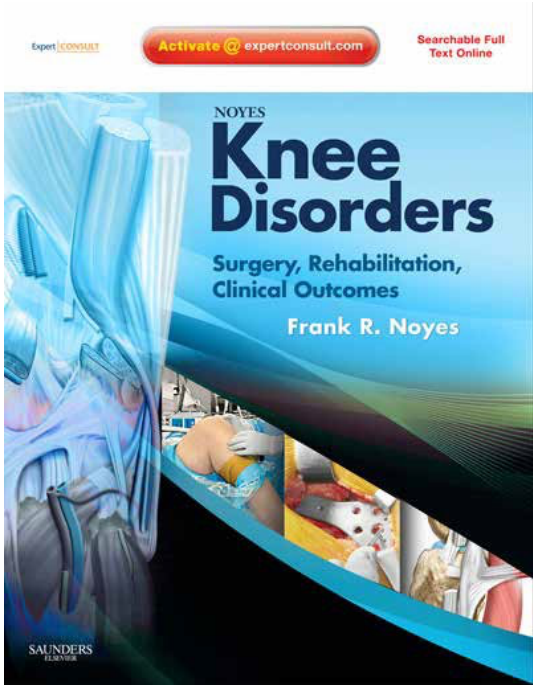

Noyes Knee Institute eBook Series

ACL Injury: Everything You Need to Know to Make the Right Treatment Decision

ACL Injury Rehabilitation: Everything You Need to Know to Restore Knee Function and Activity

Bowed Leg (Varus) and Knock-Knee (Valgus) Malalignment: Everything You Need to Know to Make the Right Treatment Decision

Exercises for Patella (Kneecap) Pain, Patellar Tendinitis, and Common Operations for Kneecap Problems

Knee Meniscus (Cartilage) Tears: Everything You Need to Know to Make the Right Treatment Decision

Operations for Knee Arthritis: What To Do When All Else Has Failed To Stop Your Knee Pain

Partial Knee Replacement: Everything You Need to Know to Make the Right Treatment Decision

Patellar (Kneecap) Pain and Problems: Everything You Need to Know to Make the Right Treatment Decision

PCL and Posterolateral Knee Ligament Injuries: Everything You Need to Know to Make the Right Treatment Decision

Stress Fractures, Bone Bruises, and Shin Splints: Everything You Need to Know to Make the Right Treatment Decision

The Unstable Patella (Kneecap): Everything You Need to Know to Make the Right Treatment Decision

Basic Knee Anatomy

It is important to understand basic knee anatomy, especially in terms of how the different regions of the knee joint may be affected by arthrofibrosis. In some knees, scar tissue only develops within certain areas while in others, it may be found throughout the entire knee joint. In this section, we will go over basic anatomy and some of the structures that may be affected by arthrofibrosis. In the next section, we will discuss in detail all of the parts of the knee that may be involved in the arthrofibrosis process that limit flexion and extension.

The knee is a hinge joint. It is made up of 4 bones that are held together by ligaments, tendons, and muscles. The femur (or thigh bone) is the large bone in the thigh. The tibia (or shin bone) is the large bone in the lower leg and the fibula is the smaller bone in the lower leg that lies parallel to the tibia.

The patella (or knee cap) is the small bone in the front of the knee that glides up and down as the knee bends and straightens. It is located in front of the femur and glides through a groove called the trochlear (or patellar) groove. As the knee bends and straightens, the patella glides up and down through the trochlear groove. The patella also moves side to side, and tilts and rotates with knee motion.

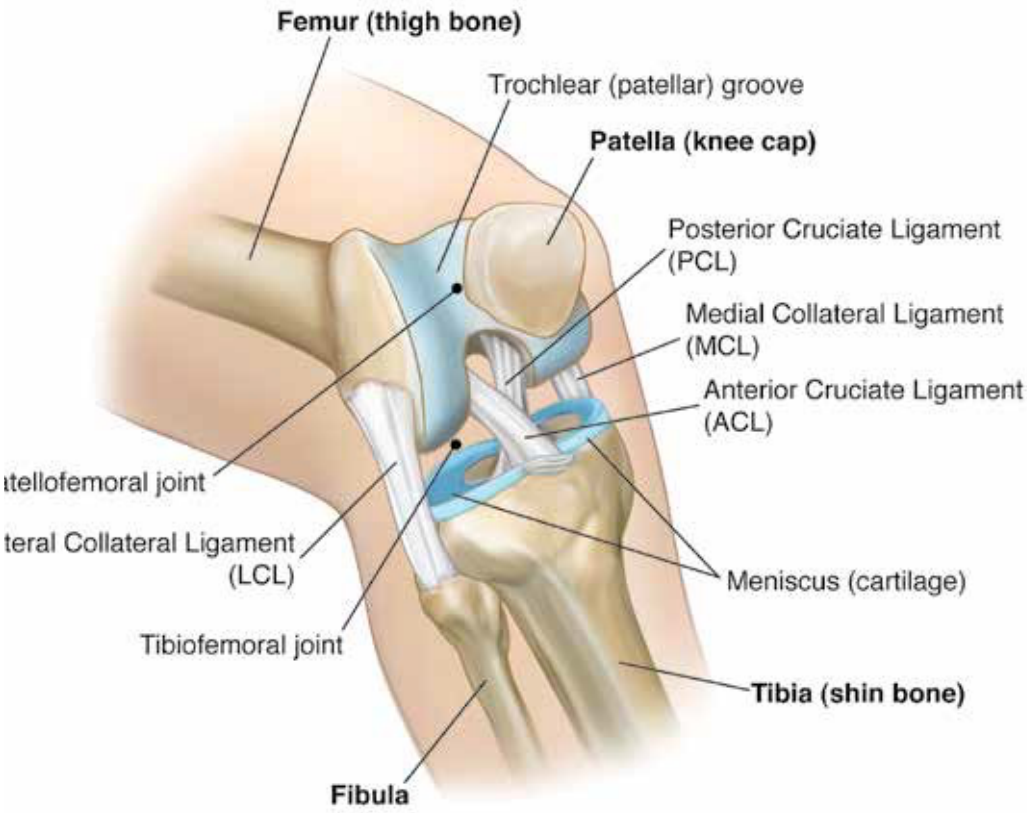

There are 2 joints, or articulations, in the knee. The tibiofemoral joint is the area where the femur and tibia meet. The patellofemoral joint is the portion of the knee where the patella and femur meet.

There are two large, strong tendons that connect the patella to the bones and muscles that surround the knee. The patellar tendon (also called the patellar ligament) connects the quadriceps muscles (the 4 large muscles in front of the thigh) and patella to the upper part of the tibia, called the tibial tuberosity. The quadriceps muscles are the rectus femoris, vastus lateralis, vastus intermedius, and vastus medialis. The quadriceps tendon connects the quadriceps muscles to the patella.

These structures may shorten within 4-6 months in the arthrofibrosis process and permanently limit knee flexion.

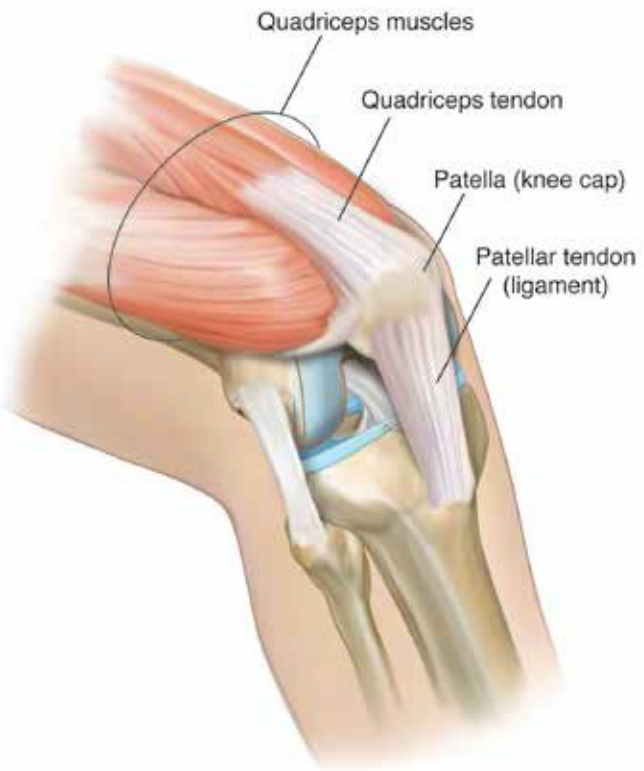

The term "extensor mechanism" refers to the quadriceps muscles, quadriceps tendon, patella, patella tendon, medial retinaculum, lateral retinaculum, medial patellofemoral ligament, and the tibial tubercle. These structures propel the legs forward when you walk, run, or jump. The medial and lateral retinaculum are soft tissues that help stabilize the patella, preventing a dislocation. Scar tissue in these structures limits knee flexion.

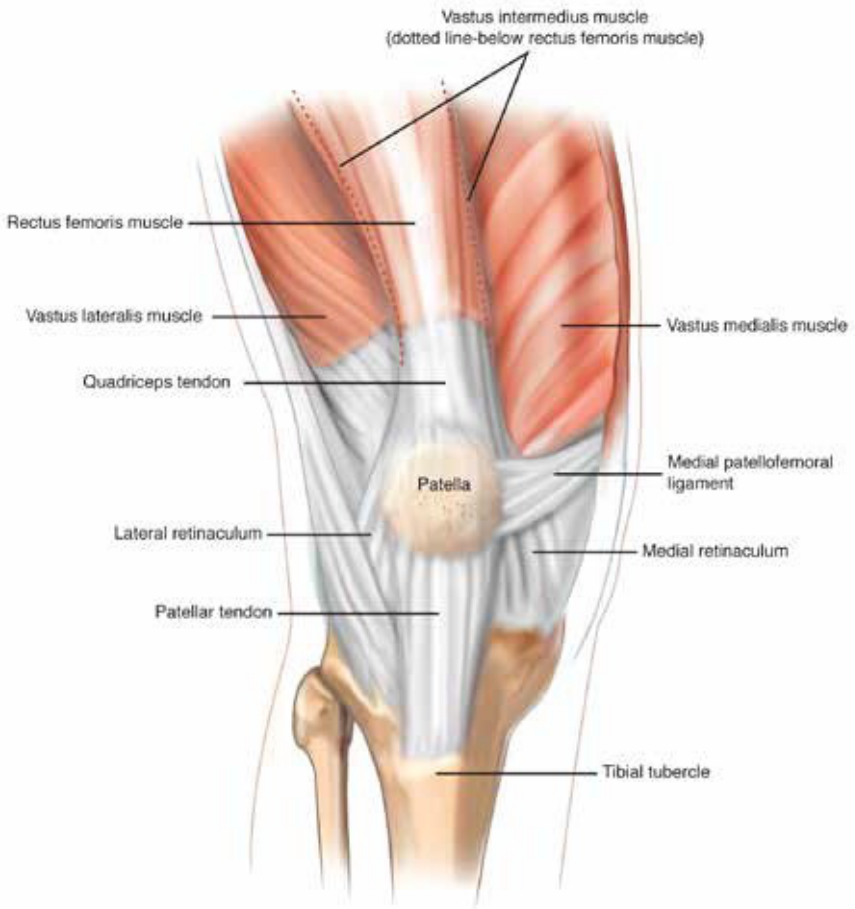

The infrapatellar fat pad lies behind and on either side of the patellar tendon. This tissue fills the space from the patellar tendon all of the way to the cruciate ligaments. It also extends sideways, making the bulge that one can often see in a normal knee on either side of the patella. The fat pad is separated from the patellar tendon by a deep infrapatellar bursa. Scar tissue in this area (called an infrapatellar contracture) can seriously limit the normal movement of the patella.

There are areas in the knee known as soft tissue "spaces" which are areas between soft tissue and bone. These include the suprapatellar pouch and capsular pouches. The suprapatellar pouch is the fold of the normal joint space that creates a pouch above the patella. The capsular pouches are located on either side of the knee (medial and lateral). There are like your cheeks in your mouth and have a normal amount of extensibility or flexibility. Scar tissue in this area limits knee flexion.

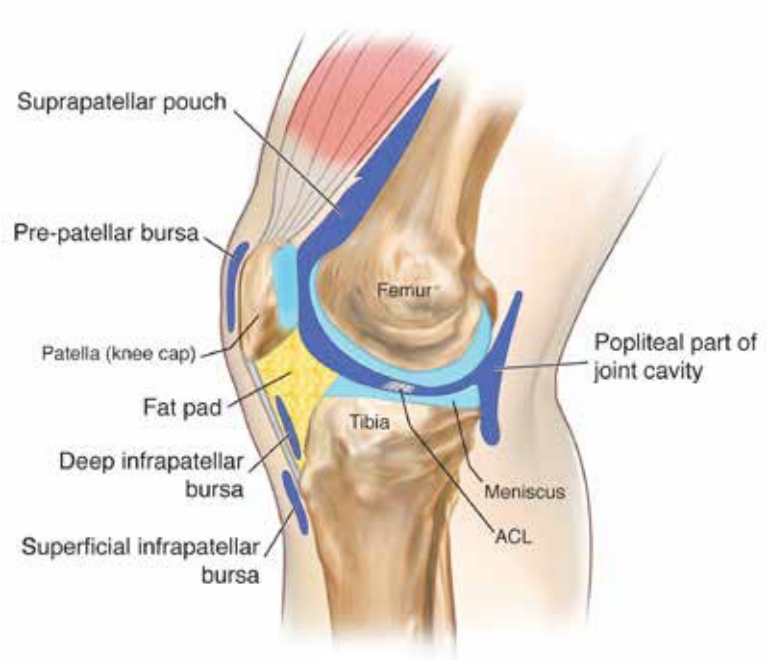

There are 2 types of cartilage in the knee joint: the meniscus (fibrocartilage) and articular cartilage (hyaline cartilage). The meniscus is a C-shaped structure that is located between the weight-bearing ends of the femur (femoral condyle) and tibia (tibial plateau). There are 2 menisci in each knee, the medial meniscus (located on the inner side) and the lateral meniscus (located on the outer side). The menisci are located on the top of the tibia.

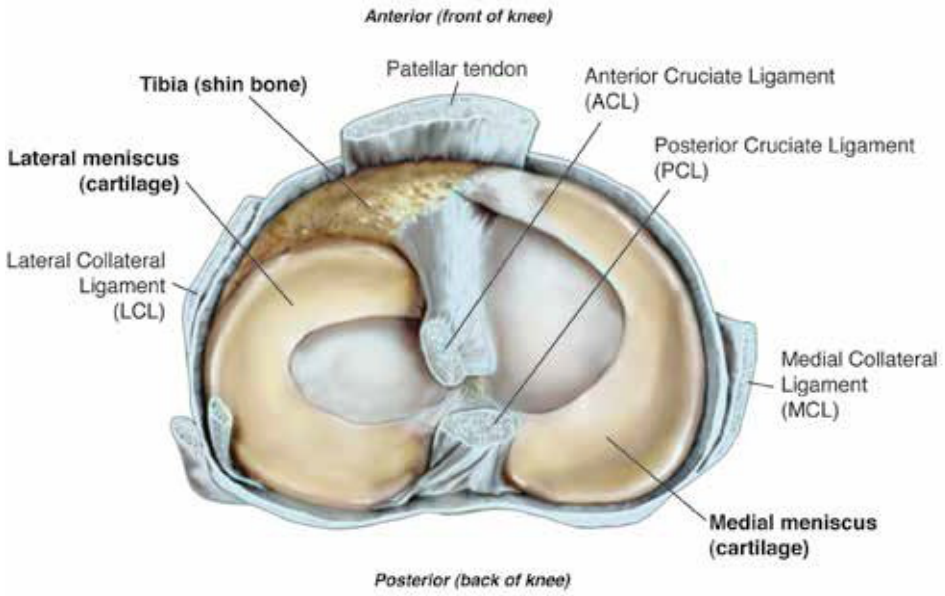

Articular cartilage is a smooth protective lining or layer of tissue that is located on the ends of bones where they meet in the knee. In the knee joint, articular cartilage is located on the end of the femur, the top of the tibia, and on the undersurface of the kneecap. This type of cartilage allows the bones to glide smoothly and the knee to flex and straighten easily. The term arthritis basically refers to the breakdown or damage to articular cartilage.

Ligaments connect bones and help provide stability to joints. Each ligament has a main job in helping to keep the knee stable when we walk, run, go up and down stairs, kneel, and do any weight bearing activity. There are 4 main ligaments in the knee. The anterior cruciate ligament and the posterior cruciate ligament cross each other in the center of the knee. They each connect the femur to the tibia. The medial collateral ligament is located on the medial (or inner) side of the knee and it also connects the femur to the tibia. The lateral collateral ligament is located on the lateral (or outer) side of the knee and it connects the femur to the fibula.

There are smaller ligaments that also exist in the knee, such as the meniscotibial ligament that attaches the edges of the menisci to the top of the tibia. The transverse ligament connects the lateral meniscus to the medial meniscus. The medial patellofemoral ligament attaches the inner edge of the patella to the medial portion of the femur. The popliteofibular ligament and fabellofibular ligament connect the femur to the top of the fibula. The hamstrings muscles at the back of the thigh attach to the tibia at the back of the knee via the semitendinosus, gracilis, and biceps tendons. The hamstrings (called the biceps femoris, semitendinosus, gracilis, semimembranosus) flex or bend the knee. The formation of scar tissue in these muscles may cause them to shorten, produce muscle spasms, and limit knee extension.

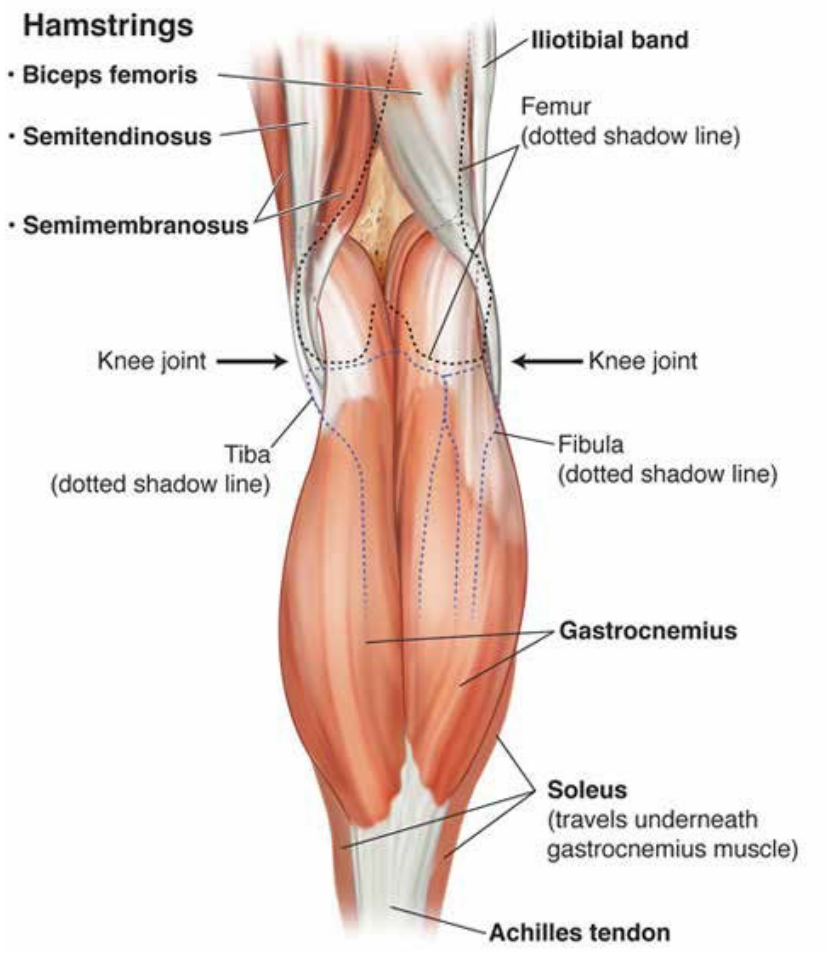

Other muscles are also important in providing stability during walking, running, and the like. These include the muscles in the hip (gluteus maximus, gluteus medius, piriformis, adductor muscles) and in the calf (gastrocnemius and soleus).

The iliotibial band is a large band of thick tissue located on the outside of the thigh. It extends from the hip to the knee. This structure also helps to stabilize the knee joint during activities such as running.

What is Knee Arthrofibrosis?

Basic Definition and Classification Systems
Arthrofibrosis is a complication of a knee injury or surgery where an excessive scar tissue response leads to painful restriction of knee flexion (how much it bends), extension (how much it straightens), or both. Knee flexion and extension is referred to as range of knee motion (ROM).

The scar tissue may form intra-articularly (within the joint) and extra-articularly (outside the joint) and persist despite physical therapy that includes knee ROM, strengthening, and stretching exercises.

There are many conditions or risk factors that may cause arthrofibrosis. These include a serious injury to the knee, an infection, an operation that has been done incorrectly, poor or non-existent physical therapy, and so on. When the condition is triggered by these conditions or problems, it is referred to as secondary arthrofibrosis because the scarring is a local problem and not part of a generalized healing disorder. This is the case in nearly every patient we have treated. We will discuss all of the potential conditions and problems that may result in secondary arthrofibrosis in detail in the next section of this eBook (How Does Knee Arthrofibrosis Happen?).

However, arthrofibrosis can also occur without predisposing conditions in patients who have a general problem with scar tissue biology, and who tend to normally produce excessive scar tissue in response to any injury or surgery anywhere in the body. In these cases, the condition is termed primary arthrofibrosis. This is believed to be extremely rare, representing about 1% of all patients who are diagnosed with arthrofibrosis.

Many different terms have been used in the medical literature to describe, define, or classify a limitation of knee flexion and extension:

Anklyosis is a generic term that indicates stiffness of a joint that occurs for any reason and may represent a loss of flexion, extension, or both.

Motion loss is another general phrase used to describe differences in the amount of flexion and extension between the affected knee and the contralateral, normal knee in the same person.

Flexion contracture indicates a loss of knee extension due to any cause.

Arthrofibrosis describes a specific cause for a limitation of knee motion, which is the formation of proliferative scar tissue or fibrous adhesions within a joint.

When discussing arthrofibrosis, it is useful to refer to grading systems, such as the one described by Dr. Donald Shelbourne. He categorized arthrofibrosis into 4 types based on the difference from full flexion and extension of the opposite, normal knee:

Type 1: < 10 degree extension loss and normal flexion
Type 2: > 10 degree extension loss and normal flexion
Type 3: > 10 degree extension loss and > 25 degree flexion loss with a tight patella
Type 4: > 10 degree extension loss, 30 degrees or more flexion loss, and patella infera with marked patellar tightness

We define arthrofibrosis with what is called an anatomic classification system. This system identifies all of the areas in the knee where the scar tissue exists. In some patients, scar tissue only develops in certain areas while in others, it is present throughout the entire knee joint.

In our experience, identifying all of the areas where scar tissue is present is the key to diagnosing and treating this complication. The areas that may be affected by arthrofibrosis are:

- The tibiofemoral joint(s) (medial, lateral, or both)
- The patellofemoral joint
- Quadriceps muscles
- Quadriceps tendon
- Patellar tendon
- Patella
- Infrapatellar fat pad
- Medial and lateral patellar retinaculum
- Iliotibial band
- Medial patellofemoral ligament
- Cruciate ligaments
- Transverse ligaments
- Suprapatellar pouch
- Capsular pouches
- Posterior capsule
- Femoral notch
- Hamstrings muscles

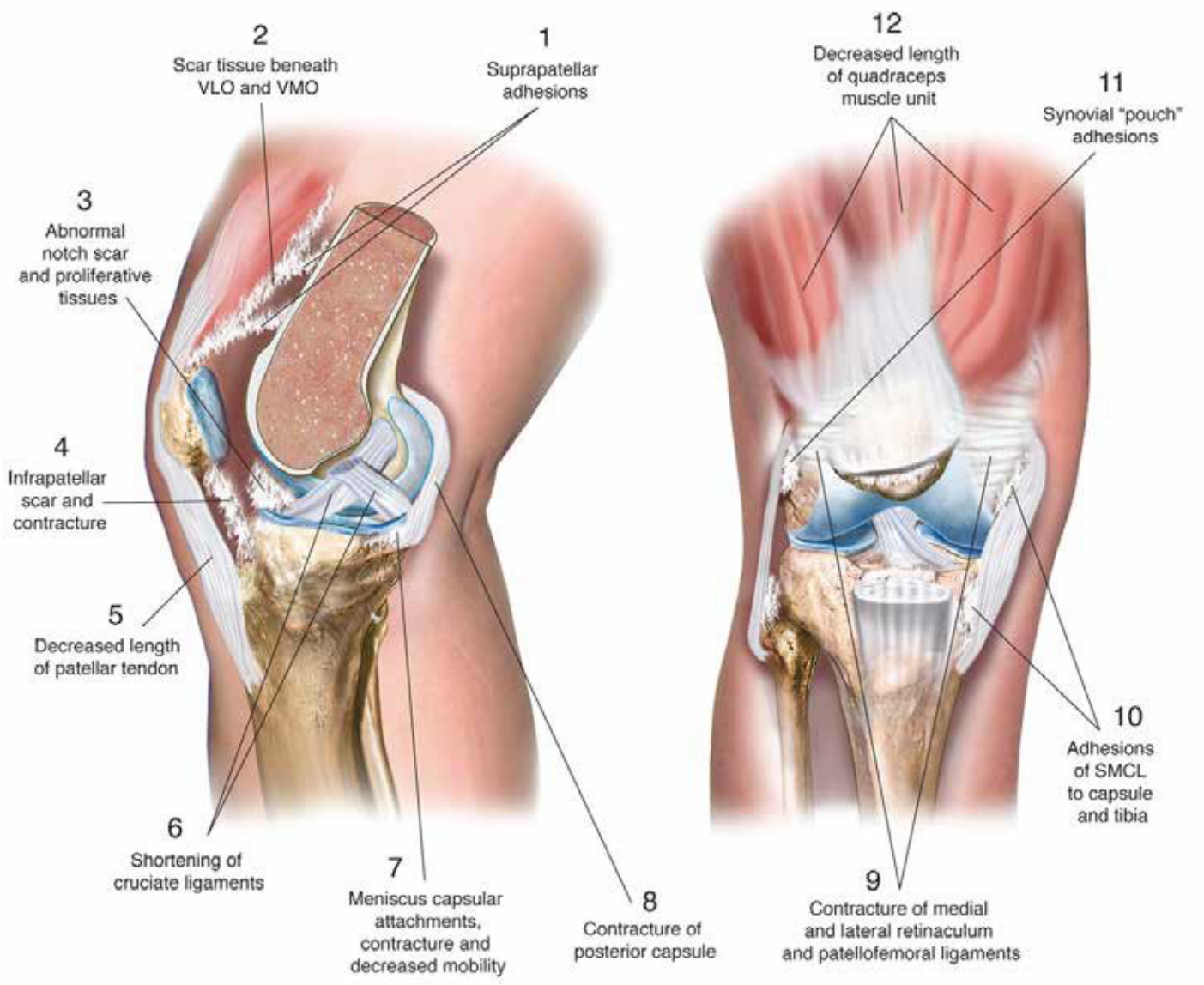

Structures Involved With Loss of Knee Flexion

Suprapatellar pouch. A limitation of knee flexion is frequently associated with the loss of soft tissue joint spaces (suprapatellar and capsular pouches). Adhesions stretching across the knee joint spaces mature into fibrous tissue. This fibrous tissue slowly contracts, closing these spaces. When the suprapatellar pouch scars down, scar tissue may be found underneath the quadriceps muscles (vastus lateralis obliquus and vastus medialis obliquus), or a band forms that extends to the top of the patella.

Medial and lateral capsular pouches. When the capsular pouches are involved, they may scar down to the point where they become attached to the sides (medial and lateral) of the femur.

Patellar retinaculum and associated ligaments. Loss of knee flexion may also involve fibrous tissue located on both sides of the patella, within the medial patellofemoral ligament, medial and lateral retinaculum, and iliotibial band. These areas may become very tight and produce limited patellar mobility, meaning the kneecap does not move in its normal manner up, down, or sideways.

Quadriceps muscle. The quadriceps muscles may shorten due to scar tissue and atrophy, which limit normal muscle lengthening.

Infrapatellar fat pad. Frequently, thick bands of scar tissue form in front of the fat pad which becomes thickened and fibrosed. The deep infrapatellar bursa may be obliterated. The scar tissue may adhere to the anterior horn of the medial and lateral menisci, the patella, and the patellar tendon, and may fill the front of the knee joint. This thickened scar tissue may also become tethered to the intercondylar notch where the cruciate ligaments are located.

Medial and lateral extra-articular tissues and ligaments. These structures, such as the superficial medial collateral ligament (SMCL) may scar, form adhesions to the capsule and tibia, and shorten.

The position of the patella is of great concern in knees with arthrofibrosis. The pain and restricted ROM in an arthrofibrotic knee may lead to a series of events that include atrophy (wasting) and shortening of the quadriceps muscles, shortening of the patellar tendon, and scarring and contracture within the tissues that surround the patella. The patella may be pulled downward from its normal position in relation to the femoral sulcus and tibial plateau, thus altering the normal mechanics of the patellofemoral joint and the entire extensor mechanism. This is referred to as patella infera, or patella baja. This problem usually causes serious damage to the articular cartilage (arthritis) underneath the kneecap. We will talk more about patella infera later in this eBook.

Structures Involved With Loss of Knee Extension

The anatomic causes of limitation of knee extension are entirely different than those we just described for limitation of flexion. Four anatomical structures are of particular concern.

Posterior capsule. Located in the back of the knee, the posterior capsule is a complex fibrous structure that encloses and supports the joint cavity. It has folds in it that, in the arthrofibrosis process, get tight from scar tissue and adhesions and are subsequently lost.

Femoral notch. The femoral notch is where the cruciate ligaments are located. This area may have excessive scar tissue that causes pain with extension.

Hamstrings muscles. The hamstring muscles may shorten and become very tight.
Cruciate ligaments. In knees that have not achieved full extension for many months, the anterior cruciate and posterior cruciate ligaments may shorten and limit extension.

Effects of Loss of Knee Motion

Most people have the same amount of flexion and extension in the right and left knee. Here are average ROM values (extension-flexion) for women and men from the Normal Joint Range of Motion Study from the Centers for Disease Control and Prevention:

Age 9-19: Women 2.4-142.3 degrees; Men 1.8-142.2 degrees
Age 20-44: Women 1.6-141.9 degrees; Men 1.0-137.7 degrees
Age 45-69: Women 1.2-137.8 degrees; Men 0.5-132.9 degrees

Other studies have found that most individuals have some amount of hyperextension, where the knee goes a little past 0 degrees, resulting in a negative number. This averages -5 degrees in men and -6 degrees in women.

When you walk, as the knee goes to 0 degrees, what is termed a normal "screw-home" mechanism occurs. This allows the knee to be stable in extension during walking, with the quadriceps muscle relaxed. Some people are double-jointed and have excessive hyperextension that can also occur as a result of a ligament injury. Here is an example of a significant amount of knee hyperextension.

At least 90-120 degrees of flexion is required for normal activities such as rising from a chair and going up and down stairs. Kneeling and squatting require an even greater amount of knee flexion. Patients who have less than 90 degrees of flexion are greatly inhibited when attempting to squat, kneel, sit, or climb stairs. In athletes, even smaller deficits in knee flexion may affect performance. For instance, a loss of 10 degrees or more of flexion has been found to decrease running speed.

Loss of knee extension is even more problematic. The loss of just 5 degrees of extension affects your ability to walk normally and may cause a limp. This in turn may cause future problems with your hips and back. A real problem with poor gait is that high pressures are placed upon the patellofemoral joint (kneecap) which, over time, may result in pain and damage to the articular cartilage underneath the patella (arthritis).

A person can get by with a loss of a few degrees, where they may not even notice the difference. Even so, after a knee injury or surgery, the goal is to obtain the same amount of ROM in the injured knee as the opposite knee. The significant problem of arthrofibrosis is that the scarring within the knee joint prevents the achievement of a full ROM.

Below are two arthroscopic photographs. The photo on the left shows the tibiofemoral compartment of a normal knee, including the end of the femur (condyle), the top of the tibia, and the meniscus. The photo on the right shows a knee with advanced arthrofibrosis that has a dense growth of fibrous scar tissue and overgrown synovium obscuring the normal anatomy. You can imagine how this amount of scar tissue limits the knee's normal ROM.

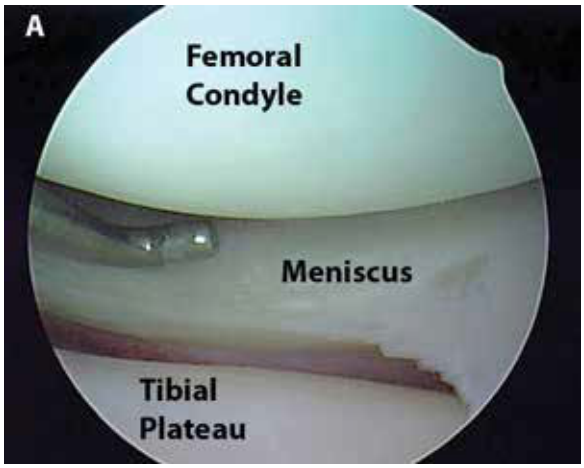

How Does Knee Arthrofibrosis Happen?

How the Body Normally Heals After an Injury or Surgery

Before we discuss how knee arthrofibrosis happens, it is important to describe how the body normally heals after an injury or surgery as it relates to this potential devastating complication. The following is not meant to be a description of the entire process of healing. We bring to light just a few factors that appear to be associated with arthrofibrosis when the body's normal healing process goes wrong.

In a normal state (uninjured), tissue homeostasis exists throughout the body. Homeostasis means the maintenance of constant conditions in an internal environment. Tissue homeostasis "encompasses the more complex biologic phenomenon of normal physiologic processes of volumes of living cells" (Dr. Scott Dye).

Homeostasis depends on constant signaling of cytokines or locally acting growth factors both between local cells and within cells. Cytokines are small proteins released by cells. They act as messengers between cells that regulate the normal cellular processes in the body, along with its response to injury, disease, and infection. Cytokines are released into either the blood stream or directly into tissue. They coordinate cell growth, maturation, and death and regulate various inflammatory responses that we will talk about next. Cytokines regulate all aspects of tissue remodeling and recovery and may act positively or negatively on tissue damage.

Growth factors are naturally occurring substances (proteins or steroid hormones) that can stimulate cell growth, rapid reproduction, and maturation. Sometimes, the terms growth factor and cytokines are used interchangeably. The difference is that growth factors have a positive effect on cell division, while cytokines may have either a positive or negative effect.

One cytokine, interleukin-1, has been found to stimulate platelets and macrophages to release a variety of growth factors, including transforming growth factor-beta (TGF-beta). TGF-beta plays a critical role in beginning and ending the process of tissue repair. It is unique in that its actions enhance the accumulation of extracellular matrix (such as scar tissue) and regulate the actions of other cytokines.

Following surgery or injury, the body sets off what is called an inflammatory cascade; a process that it uses to fight infection and protect itself. This process may result in redness, swelling, heat, pain, and a reduction in knee ROM and function. This inflammatory response usually calms down by approximately 2-4 weeks after the injury or surgery. This is followed by tissue healing and repair.

Following tissue damage (from an injury or surgery), fibroblasts (cells in connective tissue and collagen) head to the wound site and proliferate, producing abundant levels of extracellular matrix proteins. Many of these fibroblasts change into myofibroblasts that contain the features of both the fibroblast and a smooth muscle cell. The myofibroblasts express high levels of alpha smooth muscle alactin (alpha-SMA) that help facilitate wound healing. Normally, as the healing process loses its inflammatory component, there is a reduction in the production and activity of these myofibroblasts.

The initial scar tissue that forms after an injury or surgery is immature and extensible. Later, if this tissue has not been stretched with appropriate exercises, it may mature into strong fibrous tissue that cannot be stretched out to allow normal motion in the joint. We will discuss later in this eBook the necessity for immediate motion and specific stretching exercises that will help prevent the formation of thick, fibrous scar tissue.

Abnormal Healing Response in Arthrofibrosis

In cases of arthrofibrosis, the same initial inflammatory cascade occurs, but it then becomes unpredictable and exaggerated which is destructive rather than constructive, leading to considerable tissue damage and scarring. The problem is that an overproduction of TGF-beta (beyond normal levels) occurs which results in a progressive accumulation of matrix in tissues and an elevated number of myofibroblasts that leads to fibrosis. This may occur in organ systems such as the kidney, liver, and lung as well as in joints.

There is evidence that during the exaggerated fibrotic response that occurs in knee arthrofibrosis, a certain amount of tissue contraction or shrinkage occurs. We discussed this in the previous section in this eBook. alpha-SMA is responsible for the overproduction of collagen in fibrosis. TGF-beta is capable of up-regulating alpha-SMA and collagen in fibroblasts. Alpha-SMA is involved in scar tissue formation during the course of primary arthrofibrosis.

In the arthrofibrosis process, there are alterations of the extracellular matrix, including an increase of collagen type VI expression similar to other local or systemic fibrotic disorders. A chronic inflammatory pattern may indicate an immune response.

The true cause of primary arthrofibrosis is not yet known, but the current assumption is that it is genetically determined. Investigators are studying patients with primary arthrofibrosis to determine if they can identify the guilty gene or genes.

It is also possible for a patient with the primary predisposition to arthrofibrosis to experience a secondary condition that only serves to make the problem worse. Primary arthrofibrosis is an independent disease, while secondary arthrofibrosis is considered a true complication after a knee injury or surgery.

Risk Factors Associated With Secondary Arthrofibrosis

There are certain conditions or risk factors that make the knee vulnerable to arthrofibrosis:

- Magnitude of the injury: Dislocated knee, multiple ligaments injured
- Preoperative issues: normal knee motion not restored before surgery, ligament reconstruction in swollen, painful knee
- Technical factors at surgery: ACL graft placement, fixation, tensioning
- Concurrent MCL repair or reconstruction
- Infection
- Immobilization, casting
- Chronic joint effusion, severe quadriceps atrophy
- Postoperative issues: poor rehabilitation, noncompliant patient
- Complications: excessive inflammation, synovitis, complex regional pain syndrome, reflex sympathetic dystrophy, cyclops lesion, excessive scar tissue in the femoral notch

Magnitude of the Injury
Injuries that may result in arthrofibrosis include fractures near the joint, an injury or surgery complicated by a hemarthrosis (bleeding into the joint), an injury involving multiple ligaments in the knee, a knee dislocation, meniscal tears, a quadriceps rupture, and a patellar tendon rupture.

Preoperative Issues
Performing ACL and other knee ligament reconstructions within a few weeks of the injury or before the resolution of swelling, pain, quadriceps muscle atrophy, abnormal gait mechanics, and motion limitations has been noted by many researchers to increase the rate of postoperative knee motion problems. Before surgery, we follow these steps to avoid the development of a postoperative knee motion problem:

- The patient should regain full ROM unless a mechanical block exists such as a bucket handle meniscus tear.
- Knee swelling and pain from the injury should be resolved.
- A strong quadriceps muscle contraction should be demonstrated.
- The patient should be able to walk normally.

The achievement of these goals usually requires at least 4-6 weeks. The inflammatory response to the initial injury varies among patients. While some have little effusion and swelling, others have an exaggerated inflammatory response with pain, soft tissue edema, and redness and increased warmth in the tissues surrounding the knee. These patients are placed into a conservative treatment program to resolve these problems first and are also carefully monitored after the knee ligament reconstruction for a similar exaggerated inflammatory reaction postoperatively. There are some patients who have minimal swelling and good return of muscle function within 1-2 weeks of their knee ligament tear and they may undergo surgery earlier than others.

In regard to patients undergoing total knee replacement, studies have found that a lack of the normal amount of knee flexion before the operation is an established predictor of problems regaining ROM after surgery because of stiffness that exists in the extensor mechanism. It is very common to have a flexion contracture (lack of normal knee extension) due to joint arthritis, scarring in the posterior capsule, and shortening of the hamstring muscles. Every effort should be made in these individuals to gain as much flexion as possible before surgery and the patient should be instructed that they will require a more intensive physical therapy program after surgery to regain as much ROM as possible.

Technical Factors at Surgery
Improper placement of the ACL graft has been frequently cited as a cause of loss of knee motion. Grafts placed in what we call a “vertical orientation” may cause a limitation of knee motion. Grafts may become impinged in the intercondylar notch area that can limit full extension. Unfortunately, if the limitation is severe and cannot be resolved with conservative rehabilitation measures, the graft has to be removed.

Stiffness after total knee arthroplasty may be due to poor positioning or sizing of the components, inadequate balancing of soft tissues, and implant loosening. However, the most common cause is the patient not following (or being placed into) an aggressive knee motion program to overcome the preoperative motion limitations that were present. The patient should be informed before surgery that their postoperative rehabilitation will be intensive for at least 12 weeks in order to regain as much knee motion as possible.

Concurrent MCL Repair or Reconstruction
Knees that have a tear to the medial collateral ligament (MCL) in addition to the ACL are at an increased risk of knee arthrofibrosis if the MCL tear is surgically repaired with an ACL reconstruction. We recommended many years ago to treat the majority of combined ACL-MCL ruptures conservatively first to allow the MCL tear to heal, and then to reconstruct the ACL later.

Infection
Infection may result in loss of knee motion following any knee surgery. In our experience, this is the number

one cause of arthrofibrosis. The rule we follow is to always consider first that an exaggerated inflammatory response with joint swelling, synovitis, and early limitation of joint motion is caused by a joint infection until proved otherwise. Even when an infectious process appears to have been excluded, a knee joint that does not respond to the gentle modalities to regain knee motion, or that has continued pain or lack of patellar mobility, should undergo repeat aspiration, cell count, culture, and diagnostic studies.

Postoperative Issues
There is agreement among most surgeons that immobilization (casting) after knee surgery is harmful to all of the knee joint structures and may result in arthrofibrosis, prolonged muscle atrophy, patella infera, and articular cartilage deterioration. Early knee joint motion decreases pain and postoperative joint effusions, aids in the prevention of scar tissue formation and capsular contractions that can limit normal knee flexion and extension, decreases muscle disuse effects, maintains articular cartilage nutrition, and benefits healing knee ligament grafts.

Modern postoperative physical therapy programs begin immediate knee motion and muscle strengthening exercises the day following surgery, both of which have been shown to be safe and not harmful to healing grafts. Importantly, the immediate motion program must include patellar mobilization to avoid an infrapatellar contracture problem (scarring of the tissues surrounding the patella).

It is extremely important to prevent quadriceps muscle inhibition, or shut-down. The surgeon should aspirate a joint effusion when it is believed to be causing quadriceps inhibition. A sample of the fluid is usually sent for culture to check for infection.

A hemarthrosis (irritating blood in the joint) should be drained. Pain and inflammation need to be controlled by using the RICE (rest, ice, elevation) regime, non-sterodial anti-inflammatory medications, and adequate pain medication. In certain instances, steroids are given intravenously before and after major knee surgery to decrease the inflammatory response.

Patient compliance with the postoperative rehabilitation program is essential to recover full knee motion and function. In our experience, the small percentage of patients who have permanent restrictions in extension or flexion have often been unwilling to perform the required motion, strengthening, and patellar mobilization exercises at home to maintain the goals achieved with their therapist.

In addition, in instances where an early postoperative limitation of motion has been recognized, these patients are also unwilling to undergo treatment recommendations such as overpressure exercises, extension casts, and other modalities that are usually effective in resolving these problems. Thus, in a majority of cases, the inflammatory and fibrotic response that follows surgery and initially limits knee motion is treatable if no delay occurs in instituting a gentle motion and overpressure program along with appropriate anti-inflammatory medications.

There is a very small group of patients, probably in the range of 1-2%, that demonstrate a pathologic exaggerated fibrous tissue proliferative response from a genetic basis, in which the treatment is prolonged and may not be successful. They may still be helped by the overall program to regain as much motion as possible.
The early detection of a knee motion limitation is crucial in the prevention of a permanent arthrofibrosis and this is discussed in detail later in this eBook.

Complications
Postoperative complications may result in arthrofibrosis. These include excessive inflammation, synovitis,

development of a pain syndrome (complex regional pain syndrome, reflex sympathetic dystrophy), or development of a cyclops lesion. Infection in the knee joint, which we already discussed, is the number one cause of severe intractable arthrofibrosis. The early diagnosis and treatment of these complications is critical to avoid a knee motion problem.

The photograph below show a severe limitation of knee extension (A) and flexion (B). This patient came to us 10 weeks after ACL reconstruction. Because the patient had poor rehabilitation and the ROM problem was not treated early, they required further surgery.

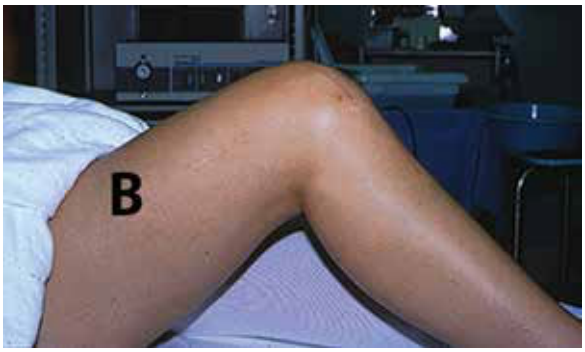

How is Knee Arthrofibrosis Diagnosed?

Early Detection

The early detection of a limitation in ROM is critical for resolving the problem and preventing permanent arthrofibrosis. This is why, as we will discuss in the next section, the surgeon and physical therapist should have specific knee flexion and extension goals and time frames for the achievement of these goals for different knee operations.

At our Center, all patients need to achieve full knee extension as soon as possible and by at least 1 week after surgery, regardless of what operation was performed. Usually, 90 degrees of knee flexion is also a goal to reach by the 7th day after surgery. If patients fail to achieve this amount of knee motion, they are immediately placed into our overpressure (stretching) program, which we describe in detail in the next section of this eBook.

The patient's ROM should be carefully documented after surgery by the physical therapist. We believe patients should be seen by the surgeon and therapist within 48 hours of any operation. The medical team can determine if the patient's quadriceps muscle has "turned on" and that they can make a muscle and lift their leg off of the exam table. They can also make sure the patient is performing the initial exercises correctly, including ROM and patellar mobilization. We strongly disagree with letting a patient wait a week or more after surgery before seeing the surgeon and therapist.

Depending on the operation, patients should be seen in supervised physical therapy sessions 1-2 times a week for several weeks. This approach allows for the early detection of any problems with knee motion, patellar mobilization, and muscle function. The initial phase of arthrofibrosis occurs within the first few weeks after surgery. The condition at this time period is called transient because the limitations in ROM are usually resolved with conservative measures that we will describe, as long as the patient follows the recommend program.

Here are some warning signs that an arthrofibrotic process may be underway:

Flexed knee gait. The patient walks with a flexed knee gait, meaning they keep their knee always bent and never straight. The surgeon should determine if this is happening because the quadriceps are inhibited or weak, or if there is a mechanical block to extension.

Worsening pain. Pain is a normal feature of injury and surgery, but usually settles down in a predictable manner. When pain does not resolve or becomes worse, arthrofibrosis must be excluded. Characteristically, pain may also happen when the quadriceps contracts and there may be tenderness when the surgeon palpates around the patella and patellar tendon. When pain is severe, it is important to also keep in mind the disorder of complex regional pain syndrome that needs to be excluded, as we will discuss later.

Weak, wasted quadriceps. An inability to voluntarily perform a strong quadriceps contraction in the initial 1-2 weeks following knee trauma or surgery is a real problem. There may be no tension in the patellar tendon and the patella fails to move upwards when the quadriceps contract. If not treated, scar tissue develops and the tendon permanently shortens.

Warm joint. It is normal for the knee to be warm during the acute inflammatory stage after injury or surgery. This usually resolves within 2 weeks. If the joint remains warm at this time, or any increase in warmth is suddenly experienced, infection must be excluded.

Continued tissue swelling. Tissue swelling in arthrofibrosis has a particular characteristic, making it relatively easy for the alert clinician to distinguish this from an effusion (fluid in the joint space) or hemarthrosis (blood in the joint space). The swelling associated with arthrofibrosis is located in the soft tissues around the knee, giving a sensation of tissue bogginess or edema.

Established Arthrofibrosis

If the knee motion problems go unrecognized or untreated for a few weeks, the arthrofibrosis becomes what we term resistant. At this point, treatment may still be effective but it will involve more than just overpressure exercises. We will discuss the use of oral steroids, surgical release, and in-patient physical therapy for these cases later.

Finally, if a few months go by without recognition or treatment, the arthrofibrosis becomes permanent and requires further surgery. At this point, findings may include shortening and contraction of the posterior capsule, significant scar tissue in the intercondylar notch, shortening of knee ligaments (or grafts), obliteration of the suprapatellar pouch, shortening of the quadriceps muscles, loss of patellar mobility, and severe muscle atrophy.

Patients who present with established arthrofibrosis require a comprehensive medical evaluation. This may include x-rays, bone scans, and magnetic resonance imaging (MRI).

The knee examination may demonstrate widespread edema, increased warmth about the knee joint, constant pain, limited patellar mobility, contracture of the peripatellar and infrapatellar soft tissues, tenderness in the fat pad, and limits in both extension and flexion compared to the opposite, normal knee. Anterior knee pain, stiffness, pain with attempted knee motion, a flexed-knee gait, and severe quadriceps atrophy are common findings.

Several x-rays should be obtained, including weight-bearing posteroanterior, anteroposterior and lateral. The

vertical height of the patellar in both knees should be measured as shown in the illustration below.

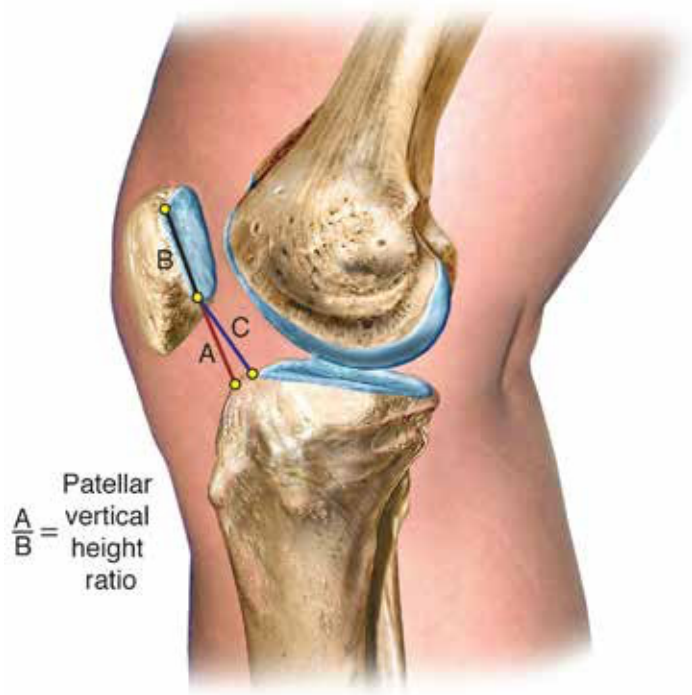

A decrease in the height of 14-15% indicates a patella infera condition, which is a real disaster that we will discuss in detail later in this eBook. The pain and restricted ROM from arthrofibrosis causes atrophy (wasting) or shortening of the quadriceps muscles, shortening of the patellar tendon, and scarring in the tissues that surround the patella. The patella is pulled downward, thus altering the normal mechanics of the patellofemoral joint and the entire extensor mechanism. This problem usually causes damage to the articular cartilage (arthritis) underneath the kneecap, along with severe disability.

Below are x-rays of a 14-year old female gymnast who was referred to our center just 4 weeks after an ACL reconstruction that was done by another surgeon. The x-ray on the right shows the normal vertical height of her patella. The x-ray on the left shows the 22% decrease in this height.

Fortunately, the arthrofibrosis and patella infera were detected early (in the transient stage) and we were able to help resolve the problems. But, this young athlete had to undergo daily physical therapy and another operation

to remove the scar tissue and was only able to return to recreational activities.

Here are some alerts to obtain x-rays to measure the vertical height of the patellar. The lateral x-rays may need to be taken frequently:

Restricted patellar mobility. Restriction in patellar mobility when the examiner tries to move it up and down and side-to-side when compared to the opposite, normal patella.

The clinical examination of the mobility of a normal patella (left) and one that is restricted due to contracted scar tissues (right)

Restricted active and passive ROM. The patient makes early gains in ROM, but then has no further improvement. The patient may lack more than 5 degrees of extension and may have only 120 degrees (or less) of flexion.

Worsening ROM. The patient makes good gains initially, but then loses knee motion, despite aggressive exercise.

Downward migration of the patella. In an inflamed joint, there may be a transient patella infera due to fat pad and peri-patellar tissue contracture that is aggravated by quadriceps weakness. The patella may be visibly lower in position compared to the opposite normal knee. With progressing joint stiffness and limited ROM due to arthrofibrosis, the patellar tendon may permanently shorten, with the eventual onset of severe patellofemoral arthritis.

MRI is very useful to determine the extent and location of scar tissue. Surgeons and radiologists will look for an infrapatellar band of scar tissue, obliteration of the fat pad, thick peripatellar tissues, a cyclops lesion, and the location of any knee ligament grafts. In addition, any signs of an infection or unexplained edema and fluid in the soft tissues or bone are evaluated to exclude an infection.

Other Reasons for Limitations of Knee Motion

It is important to note that there are other causes for the loss of knee motion other than arthrofibrosis in and of itself. These include:

- Muscle inhibition
- Fluid in the joint (including infection)
- Mechanical factors, such as a loose body, bucket-handle tear of the meniscus, or cyclops lesion
- Joint bones out of alignment, such as from a fracture
- Interruption to the extensor mechanism, such as a ruptured patellar tendon

- Improperly placed ligament graft
- Damaged nerves

It is the surgeon's role to determine if any of these factors are present and accounting, at least partially, for the knee ROM problem. In addition, these conditions may trigger or be present in combination with arthrofibrosis.

Prevention of Knee Arthrofibrosis

Physical Therapy: Setting Goals Before and After Surgery

It is very important for patients to regain normal ROM before knee surgery. An exception is a knee replacement operation where the limitation of ROM caused by the arthritis and stiffening is fixed at surgery. In these cases, intensive postoperative therapy is required as a result of the motion limitation that was present before the operation. One other exception is a mechanical block to knee motion that usually occurs from a bucket-handle meniscus tear, whereby a portion of the meniscus tissue flips up into the joint.

In our clinic, the majority of patients must meet certain goals before surgery in terms of regaining normal ROM, good muscle strength, normal gait, and resolution of pain and swelling. Patients will frequently work with a physical therapist and perform home exercises for several weeks before surgery is considered.

The establishment of specific knee flexion and extension goals after knee surgery should be done and communicated by the therapist-surgeon team to the patient. We strongly believe that patients should meet with their physical therapist before surgery to learn these goals and receive instructions on how to perform the first basic knee exercises required after surgery. The therapist can evaluate the condition of the patient's knee and entire leg and their mental-emotional status. The patient should have a good understanding of what will be required in terms of how often exercises are to be performed and approximately how long the physical therapy program will last.

At our clinic, all patients are expected to have at least 0-90 degrees of knee motion by 7 days after any knee operation. The rest of knee flexion should then be gradually achieved, with the goal of obtaining at least 135 degrees within a few more weeks.

It is the responsibility of the physical therapist, under the direction of the surgeon, to provide the patient with a comprehensive postoperative physical therapy program to regain normal ROM, muscle strength, and normal gait (ability to walk normally). Next we will provide examples of some exercises that may be prescribed that are done at home to achieve these goals.

Exercises to Regain Knee Motion

Range of Knee Motion
This exercise is performed passively, which means that the muscles in your operated leg are relaxed and your knee is moved either by your therapist, assistant, or with your other leg. To perform this exercise at home, hang your legs over a bed, counter, or chair and use your opposite (non-operated) leg to assist in bending and straightening your knee. Place the foot of the opposite leg in front of the leg of the operated knee and push back for flexion. Place the foot of the opposite leg in back of the foot of the operated knee and pull up for extension. Go back as far as you can for flexion, hold for 5 seconds, then go up as far as you can for extension. Repeat for 10 minutes at a time, 3-4 times a day.

Passive range of motion exercise for knee flexion (A) and knee extension (B)

Wall Slides
Wall slides are an effective exercise to achieve flexion. Lie on your back on a bed or the floor and place the foot of your reconstructed knee on a wall. Place the foot of your opposite leg on top of the foot of the reconstructed knee and use it to gently flex your knee in a gradual manner by sliding down the wall. Then, reverse the position of the feet and slide them back up the wall to the starting position. Perform for 10-12 minutes at a time and repeat 6-8 times a day.

Patellar Mobilization
You may either have an assistant perform this exercise or use your own hands. Move your kneecap as far as possible to the right, to the left, up (toward your thigh), and down (toward your shin), holding each position for 10 seconds. Perform for 5 minutes after you complete your range of knee motion exercises.

Exercises to Regain Strength and Knee Function

Listed below are some simple exercises you may do at home to help strengthen and improve the flexibility of your leg and hip muscles. We strongly believe that you should be under the care of a physical therapist that can guide your rehabilitation program. There are other exercises that may be done in the physical therapy clinic under direct supervision.

Quadriceps Isometrics: Full Extension
Sit up in bed, on a couch, or on a table with your back well supported. Keeping your knee as straight as possible, contract or squeeze your thigh muscle and raise your leg off of the bed or couch a few inches. Do not allow your knee to go into hyperextension. Hold for 10 seconds, then lower the leg back down and relax. Repeat 10 times. As you become stronger, see how long you can keep your leg off of the bed or couch. Challenge yourself to hold your leg for 30, 45, 60 seconds and so on. Perform on both legs.

Quadriceps Isometrics: Multi-Angle
Sit up in bed, on a couch, or on a table with your back well supported. Use pillows placed under your knee to change the angle of the knee joint. The goal is to put the knee at approximately 90°, 60°, and 30° as shown below. For each joint angle, contract or squeeze your thigh muscle for 10 seconds, then lower the leg back down and relax. Repeat 10 times for each angle. Rest for 1 minute between sets. Perform on both legs.

Straight Leg Raise: Hip Flexion
Lie on your back. Tighten your thigh muscle, keep your knee as straight as possible, and lift your leg straight up off of the bed or floor. Hold for 3 seconds, then lower the leg back to the starting position. Perform 1 set of 10 repetitions, rest for 30 seconds, and repeat the exercise 2 more times for a total of 30 repetitions. Add weight around your ankle as the exercise becomes easy to complete. Perform on both legs.

Straight Leg Raise: Hip Extension
Lie on your stomach. Keeping your knee straight, lift your leg toward the ceiling. Hold for 3 seconds, then lower the leg back to the starting position. Perform 1 set of 10 repetitions, rest for 30 seconds, and repeat the exercise 2 more times for a total of 30 repetitions. Add weight around your ankle as the exercise becomes easy to complete. Perform on both legs.

Straight Leg Raise: Hip Abduction
Lie on your side, the opposite of the leg that is painful. Keeping your knee straight, lift the leg up sideways toward the ceiling. Hold for 3 seconds, then lower the leg back to the starting position. Perform 1 set of 10 repetitions, rest for 30 seconds, and repeat the exercise 2 more times for a total of 30 repetitions. Add weight around your ankle as the exercise becomes easy to complete. Perform on both legs.

Straight Leg Raise: Hip Adduction

Lie on your side, the one that is painful. Bend the opposite leg and place the foot on the ground in front of the other knee as shown below. Lift your leg toward the ceiling, keeping the knee straight and the toes pointed straight ahead. Hold for 3 seconds, then lower the leg back to the starting position. Add weight around your ankle as the exercise becomes easy to complete. Perform on both legs.

Straight Leg Raises With Resistance Band

In these exercises, you will perform the same motion that is done during straight leg raises, except you are standing with a resistance band or rubber tubing tied around your ankle/lower leg. Secure the other end of the band or tubing around a heavy object. You will change the position of your feet in order to work the hip adductors, abductors, flexors, and extensors as shown in the photographs below. To help maintain balance, hold onto an object and slightly bend the leg that is not being exercised. Move the foot with the band in the desired direction out as far as possible to ensure the band is tight. Perform 3-5 sets of 30 repetitions, moving the band as fast as possible. Rest for 1 minute between sets. Perform on both legs.

Straight leg raise with resistance band, hip adduction, starting position (A) and ending position (B)

Straight leg raise with resistance band, hip abduction, starting position (A) and ending position (B)

Straight leg raise with resistance band, hip flexion, starting position (A) and ending position (B)

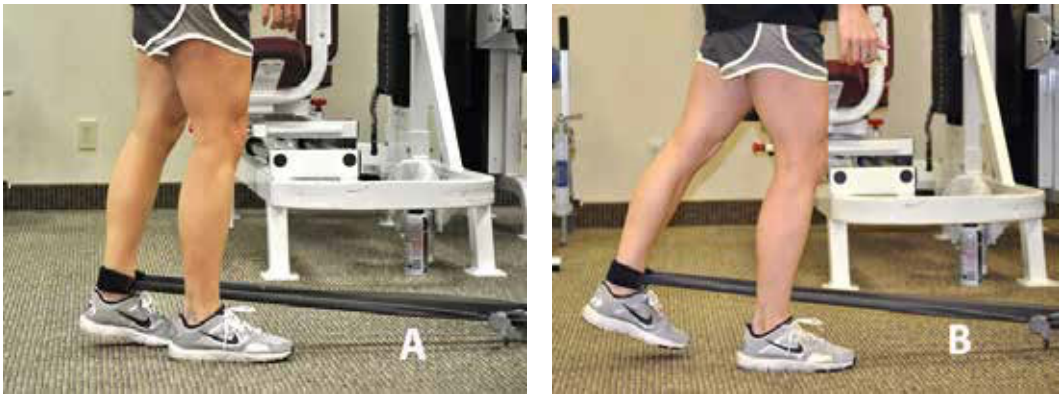

Straight leg raise with resistance band, hip extension, starting position (A) and ending position (B)

Mini-squats
From a standing position, squat down to a 45-degree angle. Hold for a few seconds and then slowly rise back up. Perform 3 sets of 20 repetitions each. This exercise may also be done on an unstable surface, such as foam, cushion, or rocker board.



Hamstring Curls, Ankle Weight
This exercise may be performed either from a standing position or lying on your stomach. Attach a small ankle weight (with the amount of weight determined by your physical therapist) and bend your knee from 0-90 degrees behind you as shown below. Perform 3 sets of 10 repetitions. Rest for 1 minute between sets. Perform on both legs.



Knee Extension, Active-Assisted

Sit up with your back well supported. Begin with your knee flexed to 90 degrees. Place the foot of the opposite leg underneath the other heel and use it to lift the leg so your knee comes up to 30 degrees. Then, tighten the thigh muscles of your leg as hard as possible, completely remove the opposite foot, and lower your leg slowly back to the 90-degree starting position. Perform 3 sets of 10 repetitions. Rest for 30 seconds between sets. Perform on both legs. Add ankle weight when able, begin with 5-10 pounds and perform 3 to 5 sets of 10 repetitions.

Wall Sits

Wear gym shoes for this exercise. Stand in front of a wall and place your feet about 2 feet away from the wall. Then, sit against the wall until your knees are flexed to 60-70 degrees. Feel the quadriceps muscles in both legs with your hands, which should feel equal. Wait until you feel a burn in your quadriceps and then hold this position as long as possible to achieve fatigue. Then, carefully stand up, rest for 2-5 minutes, then repeat the exercise. Perform 2 sets 4 times a day. As you progress, you may place a ball between your knees and squeeze it as hard as possible for the entire exercise. You may also sit a little lower, to 90 degrees if possible, provided no pain is felt in your kneecap or patellar tendon.

Toe Raises

From a standing position, come up onto the toes of your feet, raising your heels completely off of the ground. Hold for 1-2 seconds and then slowly return to the starting position. This may also be done using just one foot (single-leg). Hold onto a stable object for balance and control if necessary.

Heel Raises

From a standing position, raise the toes of your feet as high as possible while keeping the heels on the ground. Hold for 1-2 seconds and then slowly return to the starting position. Hold onto a stable object for balance and control if necessary.

Lateral Step-ups
Stand next to a step or low platform. Place one foot up on top of the platform. Then, bring your other foot up, lightly tap this foot on the platform and return it back to the starting position. Lower and raise the foot by bending and straightening your knee, maintaining good balance and posture. Repeat 10-15 times and then do the same for the opposite side. You may increase the difficulty of this exercise by holding free weights in your hands. The height of the step or platform should be no more than 12 inches and may be lower if any pain is felt in the kneecap during the exercise.

Step-downs, Stable and Unstable Surface
Begin by standing on a step or low platform. Step down slowly on one leg, then step up backwards leading with the opposite leg. Repeat 10-15 times and then do the same for the opposite side. You may increase the difficulty of this exercise by holding free weights in your hands. The height of the step or platform should be no more than 12 inches and may be lower if any pain is felt in the kneecap during the exercise. This exercise may also be done by stepping onto any unstable surface, including foam, a cushion, or rocker board.

Lunge, Straight
From a standing position, step straight ahead with one leg out as far as possible. Bend the knees and lower the back leg toward the ground. Only go down as far as you can without experiencing pain in your kneecap. Keep the front knee over the ankle and keep your back straight and head up, looking forward. Hold for 2 seconds, then return to the starting position. Repeat 10 times, rest for 1 minute, and perform 10 more times. Perform on both legs.

Lunge, Lateral
From a standing position, hop to the side with one leg as far as possible. Land on that leg, bend the knee as much as possible without experiencing any pain in your kneecap, and keep the other leg off of the ground. Balance and hold for 2 seconds, then return to the starting position by hopping back to the starting position using the opposite leg. Repeat 10 times, rest for 1 minute, and perform 10 more times. Perform on both legs.

Lunge, Diagonal
It is helpful for this exercise to create a "Y" shape on the floor with masking tape. From a standing position, hop out with one leg as far as possible diagonally (at an angle) to the left side. Land on that leg, bend the knee as much as possible without experiencing any pain in your kneecap, keeping the other leg off of the ground. Return to the starting position by hopping back with the opposite leg. Repeat 10 times, rest for 1 minute, and perform 10 more times. Perform on both legs.

Hamstrings Stretch
Sit with your leg lying straight in front of you and bend the opposite knee so that the foot is resting against the inner portion of the other thigh as shown below. Keeping your back straight, slowly lean forward until you feel a stretch in your hamstrings. Hold each stretch for 30 seconds and repeat 5 times on each leg.

Calf Stretch
Sit on a bed or recliner with a foot rest with your back well supported. Take a large towel and roll it up so that is long and thin as shown below. Wrap the middle of the towel around the toes of your leg. While keeping your knee straight, use the towel to bend your toes back toward you until you feel a stretch in your calf muscles. Hold each stretch for 30 seconds and repeat 5 times on each leg.

Iliotibial Band Stretch
Sit on the floor, bend your right knee, and keep the left knee straight and flat on the floor. Cross the foot of the right side over the left knee as shown below. Place one hand on the floor behind the hips and use the other arm to press the chest toward the knee and foot. This stretch may be done lying on the back to support the spine and neck. Hold each stretch for 30 seconds and repeat 5 times on each leg.

Quadriceps Stretch
From a standing position, grab a foot or ankle and lift it up behind your body. Gently pull the lower leg and foot up, directly behind the upper leg. Do not twist inward or outward. Hold each stretch for 30 seconds and repeat 5 times on each leg.

Treatment of Inflammation, Pain, Hemarthrosis, Infection

Knee joint effusion, inflammation, and pain are treated with appropriate non-steroidal anti-inflammatory medications, cryotherapy (ice machine), compression, and limb elevation. For major knee operations, we advise patients to stay home and remain in bed or on a couch for the first week after surgery. They keep the limb elevated at all times, except when performing their ROM and strength exercises (several times a day) or attending to personal needs. The management of pain and swelling early after surgery or injury is a crucial first step to avoiding a knee motion problem.

A hemarthrosis may occur after surgery or injury. This represents blood in the joint, which varies in terms of the amount and how it is treated. A mild hemarthrosis has approximately 25 cc in the joint and does not require draining. A moderate hemarthrosis, with about 50 cc in the joint, definitely requires draining because it will shut down the quadriceps and hamstrings. Severe hemarthrosis, with greater than 50 cc in the joint, also requires draining because the knee joint is very tense and painful.

When a knee is not responding in a normal manner and scar tissue has formed, an infection must be suspected until proven otherwise. Signs of infection may be obvious and in these cases, the knee is drained via surgery performed immediately. However, there are cases where the joint shows very little (if any) swelling, but scar tissue has developed and the joint is warm. Commonly, there will be chemical abnormalities that can be measured in the blood. However, in some cases, all cultures are negative and it becomes a dilemma as to how to treat the patient. The decision to perform arthroscopy and obtain a tissue specimen for analysis and culture, and/or treat the problem with antibiotics, is difficult and individualized to each patient by the consultant team. In total knee replacement patients, a biofilm may develop on the metallic components that contains bacteria which is resistant to treatment, requiring a two-stage revision procedure.

First-Line Treatment

One problem in published studies is a lack of agreement regarding how to recognize an early problem with knee motion, how to treat it, and when to treat it after the injury or surgery. For instance, our review of published studies found that some surgeons do not recommend an extension cast for a limitation of extension until many months after surgery. Our program incorporates this treatment 4-12 weeks after surgery if required. While some surgeons recommend a manipulation under anesthesia between 4-8 months after surgery for a knee motion problem, we instead perform a very gentle ranging of the knee under anesthesia as early as 3 weeks postoperative if the patient is delayed in regaining flexion.

In two investigations involving 650 patients at our Center that underwent ACL reconstruction, 6% required and agreed to treatment intervention for a knee motion problem that was detected early postoperatively. At the final follow-up evaluation, 2% (9 patients) lacked 5° of extension. Less than .03% (2 patients) had a permanent contracture or arthrofibrosis. An extension cast was applied in 2%, gentle manipulation under anesthesia was done in 3%, and arthroscopic debridement was performed in < 1%. So you can see that an early treatment intervention program, combined with knowledge of all of the risk factors for developing arthrofibrosis, is really effective in preventing this disaster.

Medications

There are a small number of patients who develop an exaggerated inflammatory soft tissue response after surgery or injury. The clinical examination usually reveals excessive pain, joint stiffness, soft tissue edema, warmth, and redness about the knee. The inflammation is not resolved by the usual treatment methods of cryo-

therapy, nonsterodial anti-inflammatory medications (NSAID), limb elevation, and compression.

In these cases, the maximum dose of NSAID is used for 1 week. If this is not successful, a trial of oral steroids is indicated. The surgeon should always rule out an infection in these cases, with appropriate serial diagnostic tests (aspiration, erythrocyte sedimentation rate, C-reactive protein, white blood cell counts) performed as required.

A 6-day dose pack of 4-mg methylprednisolone tablets is effective when used early in the arthrofibrosis process. Six tablets are taken on the 1st day of treatment, five on the 2nd, four on the 3rd, three on the 4th, two on the 5th, and one of the 6th. During this week, forceful and aggressive physical therapy is avoided. Gentle ROM and lighter overpressure exercises are performed. In some cases, the 6-day dose pack may be repeated.

Another option is to use oral corticosteroids (prednisone 5 mg) for 4 weeks if the inflammatory symptoms return or are more severe. The usual daily dose is 30 mg in the 1st week (2 tablets taken 3 times a day), 15 mg in the 2nd week (1 tablet taken 3 times a day), 10 mg in the 3rd week (1 tablet taken 2 times a day), and 5 mg in the 4th week.

In cases of severe arthrofibrosis, oral corticosteroids may be required for 2-3 months in an effort to avoid more surgery. Complications that may arise from prolonged use of these medications include pituitary adrenal suppression, fluid and electrolyte disturbance, hyperglycemia, peptic ulcers, and avascular necrosis. In the most resistant cases, it is necessary to repeat oral steroid cycling on the off days to NSAIDS, which are prescribed at their maximum dosage.

Currently, there are no approved anti-fibrotic medications in the U.S. or Europe for the management of knee arthrofibrosis. As of the time of writing, there were no ongoing clinical trials in the U.S. regarding drug therapy for knee arthrofibrosis. This is unfortunate given the frequency of this disorder and speaks to the increased need of physicians and professional organizations to educate and bring greater attention to this serious problem. Trials are ongoing for the use of various anti-fibrotic medications (such as pirfenidone) for other fibrotic and inflammatory diseases, such as idiopathic pulmonary fibrosis.

One small case series conducted in the U.S. investigated the role of anakinra in patients with established knee arthrofibrosis. The role of interleukin-1 (a family of cytokines) in the inflammatory response is understood and appears to play a part in the development of arthrofibrosis. A small series of 8 patients were treated with an intra-articular injection of intra-articular anakinra (200 mg), a drug that can block interleukin-1. All of the patients received the injection following arthroscopic debridement and lysis of adhesions. All of the patients had improvements in ROM and most improved with regard to pain and activity level.

We remain hopeful that chemical agents will become available to treat the abnormal and exaggerated fibrotic response to injury or surgery by controlling elevated levels of fibrogenic growth factors, cytokines, and myofibroblast up-regulators.

Overpressure Exercises

As we stated earlier, it is very important for you to regain normal motion, or the ability to fully bend and straighten your knee, after surgery. Each operation has different goals for how much knee motion should be achieved according to specific time periods and these should be clearly identified by your surgeon and therapist.

For instance, at our clinic, all patients are expected to have at least 0-90 degrees of knee motion after ACL reconstruction by 2 weeks postoperatively. The rest of knee flexion should then be gradually achieved, with the goal of obtaining at least 135 degrees within a few more weeks.

We want to stress up front that aggressive, overzealous knee motion exercises can cause more harm than good, as they may result in tearing of tissues, increased inflammation, and even fractures. An early initiation of gradual stretching of early scar tissue (before it matures and becomes resistant to stretching) as described below is usually very effective. There are disturbing stories we have seen on various Internet sites of patients describing forceful manipulations done in the surgeon's office or physical therapy clinic. The belief seems to be to simply break down the scar tissue in whatever manner works, which only aggravates the situation. We strongly disagree with this approach. Patients who are unable to achieve the goals for extension and flexion should be immediately placed into what we call a gentle but persistent overpressure motion program. When begun early after surgery, these exercises usually resolve a majority of knee motion problems.

Again, it is worth emphasis that the stretching protocols used to regain knee motion must always include low-loads over time that is repeated many times a day often for 10 -15 minutes so to decrease inflammatory effects of added trauma that works to increase scar tissue production. In addition, there are commercial stretching devices and knee orthosis stretching devices that play a role to assist the patient in performing the low-duration load (over-pressure) program. The combination of a properly applied knee flexion-extension stretching (low-load over pressure) along with carefully administered anti-inflammatory medications represents a key aspect to successfully regain knee motion, in addition to surgical release of contacted scar tissue when indicated as previously discussed.

Limitation of Knee Extension

Hanging weights. One effective exercise for a limitation of knee extension involves hanging weights, where the foot and ankle are propped on a towel or other device to elevate the hamstrings and gastrocnemius that allows the knee to drop into full extension. Sit up in bed, on a couch, or on a table with your back well supported. Prop up your foot and ankle (of your operated knee) on a towel or other item to elevate the lower leg, allowing your knee to drop into extension. Hold this position for 10-15 minutes at a time and perform 6-8 times a day. Add weight (up to 20 pounds) on the lower part of your thigh to provide more pressure if needed.

Knee extension board. The option also exists to use a commercial extension device under supervision in the physical therapy clinic, such as the one shown below.

Drop-out extension cast. If these treatment measures are not effective, a drop-out (bi-valved) cast may be applied by an experienced physical therapist for continuous extension overpressure. The advantage of this technique is that the patient is in control of the process and can apply or delete wedge material as tolerated and may bath. In some patients, full extension is regained, but then gradually lost over the course of a few weeks. In these individuals, a repeat cast application may resolve the problem.

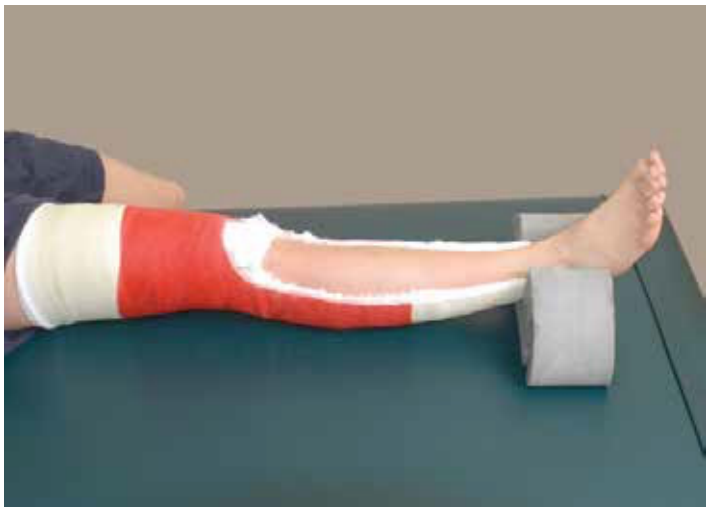

Extension casting is not recommended in knees that have greater than a -12° extension deficit with a hard block to terminal extension. These patients are usually 3 or more months postoperative and dense scar tissue has formed in the posterior capsule, causing it to contract. These patients require further surgery to remove the scar tissue, using a posterior capsulotomy that is described later. Extension casts are also not effective when there is proliferative ingrowth of fibrous tissue in the femoral notch. These cases require arthroscopic debridement.

Cylinder cast. In rare cases, the drop-out cast may not be effective and a cylinder cast and serial wedges must be used to gain extension. The cast is well padded to prevent skin breakdown. An anterior wedge is used every 12 to 24 hours to gradually achieve extension. The cast is applied for 36 to 48 hours and then removed to resume knee flexion and extension motion exercises. Once extension is regained, this cast is converted to a posterior night splint that is used for 7 to 10 days.

Limitation of knee flexion

If the patient has not achieved at least 90° of flexion by the 7th postoperative day, there are several flexion overpressure exercises which are safe and effective. The goal of these exercises and modalities is to gradually and passively stretch tissues in a controlled manner, while not inducing pain or tearing of tissues.

Rolling stool exercise. Sit on a small stool with wheels and move forward with your knee flexed to the maximum position possible. Hold that position for approximately 1 minute or as long as you can. Then, roll the stool forward without moving your foot position on the floor to gain a few more degrees of flexion and hold that position for as long as possible. Relax your knee for 2 minutes and repeat. This exercise may also be done using a large physioball. Perform for 10-12 minutes at a time and repeat 6-8 times a day.

Figure-4 overpressure exercise. As shown below, double-wrapped a 4-inch tubular stocking around the foot and ankle. Then, pull up on the stocking to flex the knee. It is helpful if the surgeon or therapist marks the thigh to show the patient the desired goal, which is usually to obtain at least 135 degrees.

Commercial knee flexion devices may also be used under supervision in the physical therapy clinic to further promote overpressure. We have found these devices to be exceptional useful because they are controlled by the patient. Using these devices, we have successfully overcome a large number of resistant cases, thereby avoiding further surgery. In some patients, the device is used at home several times a day.

Gentle Ranging of the Knee Under Anesthesia

Patients who have difficulty achieving 90 degrees of flexion, or who lack 5-10 degrees of extension by the 3 to 4th week, often require a gentle ranging of the knee under anesthesia (not a forceful manipulation). The patient receives intravenous medication in the operating room and the surgeon mobilizes the patella and then flexes and extends the knee. No more than two to three fingers of pressure are used at the distal tibia to achieve knee flexion. The patella is mobilized first to prevent damage to the patellofemoral articular surfaces. This stretches out early joint adhesions, markedly reduces postoperative pain, and allows the patient to regain motion.

We stress that this procedure gently stretches shortened tissues that are still immature and lessens the pain so the patient can successfully return to the rehabilitation program in the ensuring week. This is not the same as a forceful manipulation, which can induce significant damage to the intra-articular and extra-articular soft tissues, articular cartilage, patellar tendon, and even fracture the femur if done improperly. This is also true for pushing knee flexion in the clinic when there is no patellar mobility.

The presence of dense, resistant scar and contracted tissues surrounding the patella is a contraindication for this procedure and requires arthroscopic debridement. An operative release of tight contracture peripatellar tissues is indicated instead of overzealous flexion exercises or a knee manipulation with high flexion loads.

Role of Blood Flow Restriction Therapy (BFRT)

In the past few years there has been introduced into multiple Centers in the United States the use of a specialized rehabilitation program that involves performing exercises while a limb tourniquet is partially inflated to restrict the venous blood flow for a limited amount of time, often only a few minutes. The blood flow restriction therapy (BFRT) allows for lactic acid and other muscle metabolites to increase in concentration in the limb muscles and produces a strong positive stimulus to treat muscle weakness and restore muscle strength and function. The BFRT exercises are performed under low resistance loads that avoids large weights and forces at the knee joint that is very advantageous in arthrofibrosis patients. There are indications and contraindications for patients enrolled in a BFRT program that are explained in detail. We have recently published a review article on the safety of BFRT programs. (add SptsHealth ref). In a second major study at the Noyes Knee Institute (give publication details J Arthroscopy) we enrolled a group of patients with marked muscle weakness and atrophy, that had not responded to traditional rehabilitation programs. We reported that BFRT produced major positive changes in muscle strength in over 50% to 75% of the patients. We believe BFRT is a major "game-changer" in rehabilitation of patients with arthrofibrosis and utilize this treatment whenever possible. BFRT does requires patient education and training by an experienced physical therapist to be successful.

BFR Knee Extension with Occlusion Cuff

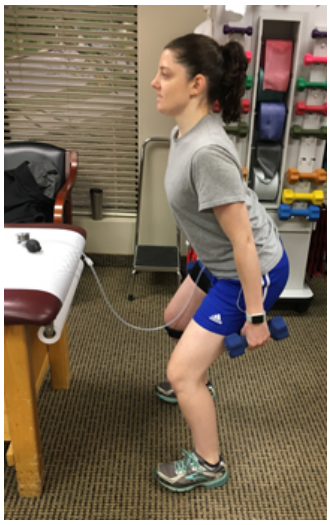

BFR Squats with Occlusion Cuff

Operative Options

Arthroscopic Lysis of Adhesions and Removal of Scar Tissues

For patients with extensive scar and contracted tissues, arthroscopic debridement and removal of scar tissue throughout the knee joint can be effective in solving a limitation of knee extension, flexion, or both. This operative procedure is indicated when:

- Usually, no more than 12-16 weeks have elapsed since the original event that triggered the arthrofibrosis – the operation or knee injury.
- Contracted tissues surround the patella, limiting mobility. The patella can be moved 50% of its normal limits (compared to the opposite patella) – medially, laterally, proximally, and distally, but it is difficult to move and can be painful.
- There is a "hard stop" during the clinical examination when the surgeon attempts to move the knee that indicates scar tissue is present throughout the knee joint.

In severe cases of established arthrofibrosis, more extensive surgery is required than an arthroscopic debridement, lysis of adhesions, and removal of scar tissue. These other operations are described later in this eBook.

A demonstration of an arthroscopic technique for debridement of contracted tissues in a knee with arthrofibrosis is shown next. This patient had a restriction in medial-to-lateral glide of the patella, with a contracture of the medial and lateral retinaculum. However, there was still 50% of normal patellar mobility present indicating that an arthroscopic technique could be used and an open extensive technique was not necessary. The ROM was 5-90 degrees.

After the patient is put to sleep, 4 small puncture wounds (called portals) are created for the operation. In this photograph, the anterolateral portal is used to cut across the lateral retinacular tissues a distance of 15 mm.

The anteromedial portal is used to cut across the medial retinacular tissues a distance of 15 mm.

The anterolateral portal is used to place surgical scissors beneath the patellar tendon. The surgeon palpates for an infrapatellar patella-tibial band of scar tissue. The scissor is pushed through this band to allow fluid to pass into the space behind the patellar tendon. This protects the patellar tendon during removal of the infrapatellar band.

There is now sufficient patellar mobility to safely pass an arthroscope beneath the patella without damaging the patellofemoral cartilage surfaces.

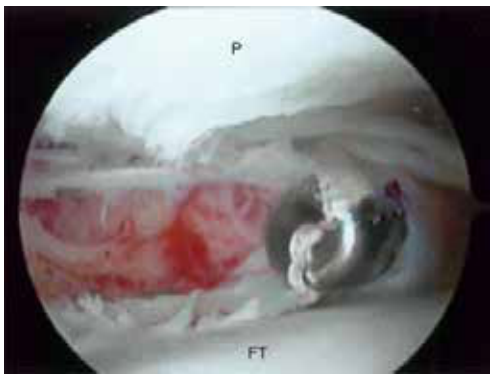

The arthroscopic photograph shows a shaver that is placed into the suprapatellar pouch and translated in a superior and inferior plane to re-establish a space sufficient for the initial arthroscopic debridement. There is a band of scar extending from the superior patella to the trochlea, and dense suprapatellar adhesions. Debridement of suprapatellar scar tissues is performed.

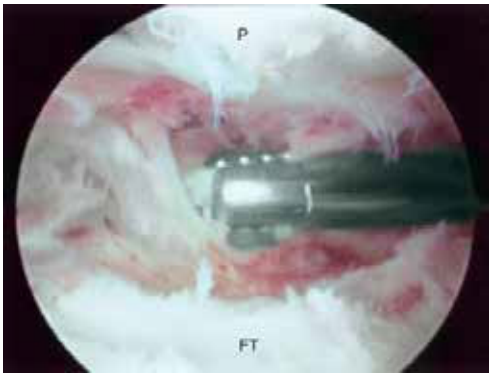

The soft tissues and synovium over the anterior femur are not removed to leave a gliding soft tissue surface.

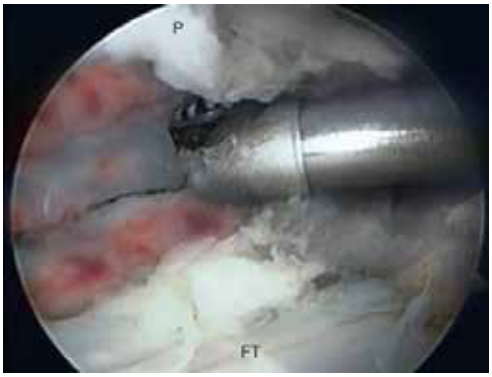

A resection of scar tissue beneath the vastus medialis obliquus (VMO) and vastus lateralis obliquus (VLO) muscles may be required because this scar can limit muscle mobility.

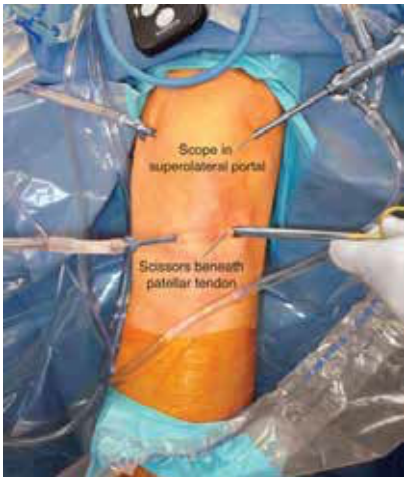

The arthroscope is placed in the superolateral portal to view the infrapatellar region and debride an infrapatellar contracture.

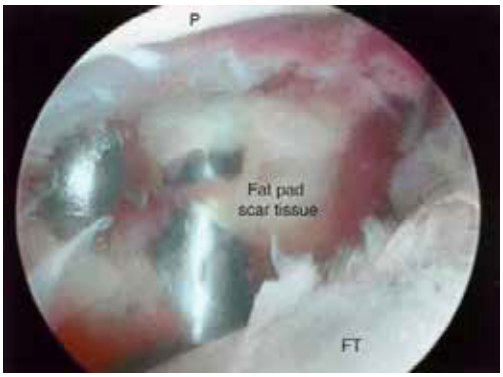

A view through the superolateral portal shows the fat pad and instruments to remove infrapatellar scar tissue. Care is taken to not transect the anterior medial and lateral meniscus attachments.

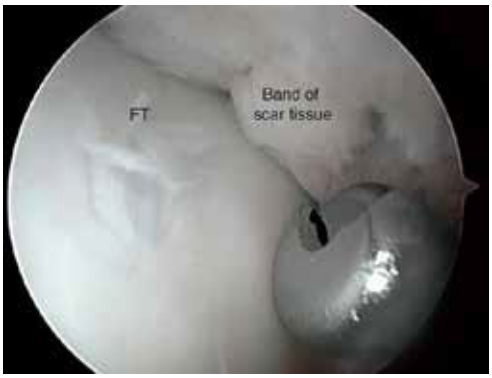

Extensive synovium and scar are removed from the medial and lateral recesses and intercondylar notch. There may exist scar tissue proliferation on the anterior aspect of the medial and lateral meniscus blocking extension that requires removal.

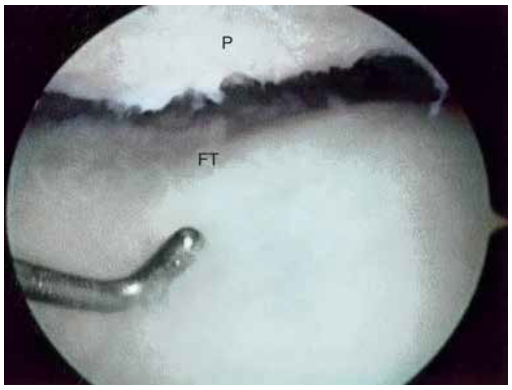

The knee is placed at 30° flexion and sufficient medial and lateral parapatellar contracted tissue and retinaculum are removed to allow for a normal medial-lateral glide. This release rarely extends above the mid portion of the patella.

Scar tissue in the notch region is removed that may block extension. In knees that had an ACL reconstruction, a notchplasty may also be required to allow full knee extension.

After completion of the arthroscopic procedure, the knee is placed into a bulky compression (cotton-ace-cotton-ace) dressing with an ice bladder incorporated into the dressing. The patient is usually kept in the hospital for 2-3 days for the intensive in-patient physical therapy program just described. Then, the patient continues with supervised physical therapy in the clinic and performs exercises at home several times a day in order to maintain the motion gained by the arthroscopic procedure.

Open Z-Plasty Release Medial and Lateral Retinacular Tissues

In cases of severe established arthrofibrosis, an arthroscopic release alone is not effective in debriding and releasing all of the scar tissue that exists throughout the knee joint. In these cases, there is no mobility of the patella and the range of knee flexion and extension is extremely limited. All other treatment measures have failed. The operation must be done through incisions. Patients are advised that 50% of the time they may achieve a benefit, 49% of the time they may not achieve a benefit from surgery, and 1% of the time they may actually be worse.

The principal of a z-plasty technique is to preserve the function of the medial and lateral retinacular soft tissues and, as well, debride the tissues to a normal thickness. The operation includes a thorough removal of contracted tissues around the patella (while protecting the patellar tendon) and a lengthening technique of contracted medial and lateral patellar tissues and shortened vastus lateralis/medialis tendons.

Preoperative examination under anesthesia of a patient with established arthrofibrosis shows a complete lack of patellar mobility, absent medial and lateral glide, and a patella infera with shortening of the patellar tendon. The ROM was 0-80 degrees.

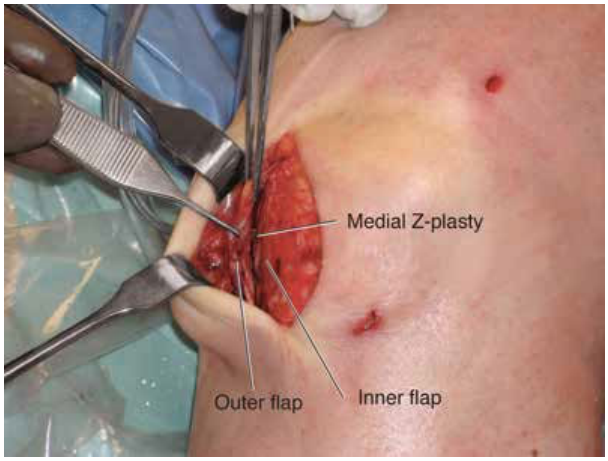

The medial retinaculum and soft tissues are split in a z-plasty fashion to allow a loose closure and restore a normal medial patellar glide. An arthroscopic procedure is performed just before the open procedure to re-establish the suprapatellar pouch, remove intra-articular adhesions within the suprapatellar pouch and medial and lateral tibiofemoral gutters, and document the condition of the joint.

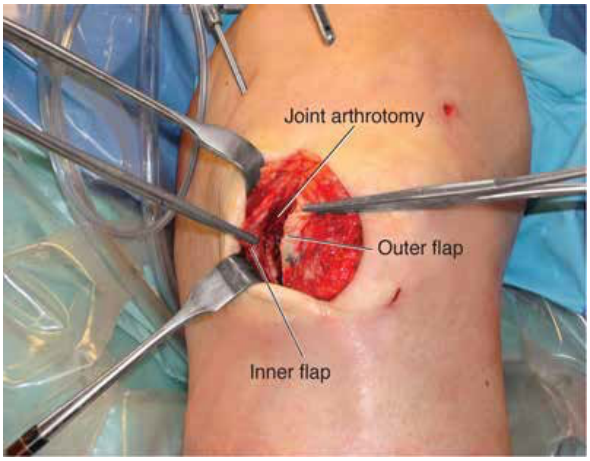

Completion of medial z-plasty release shows the medial soft tissue flaps that are developed. A debridement of infrapatellar scar tissue is performed.

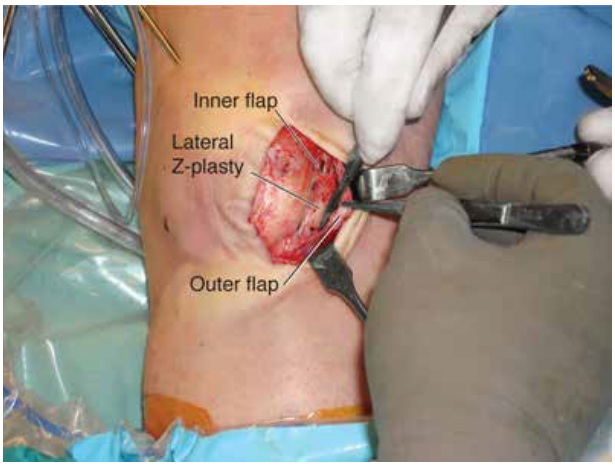

A lateral z-plasty release of contracted lateral retinacular tissues is performed.

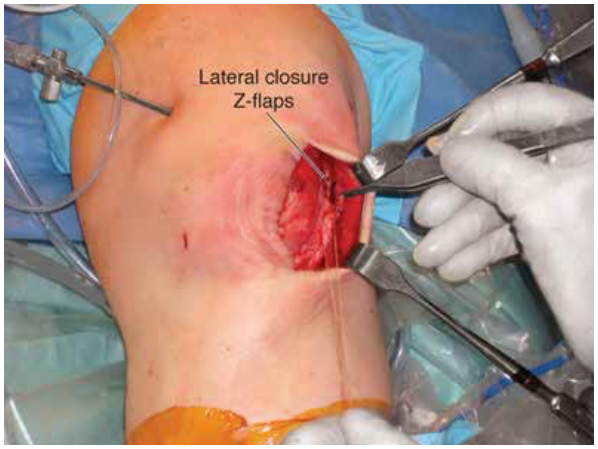

The loose closure of the lateral z-plasty release allows restoration of a normal medial patellar glide.

Open Posterior Capsulotomy

Open posterior capsulotomy (cutting open the capsule behind the knee) may be an option to allow full extension of the knee joint. There may be soft tissue calcification in the capsule and posterior structures. The posterior capsule releases are also accompanied with an arthroscopic procedure to remove any tissue that has grown into the notch that would also block extension. In knees requiring this procedure, it is often impressive how dense the posterior capsular structures are. When the releases are done, further gains in knee extension are made right on the operating table. Further extension is then achieved with the overpressure therapy program.

The photographs and illustrations below are of a patient with arthrofibrosis who required an arthroscopic lysis of adhesions, parapatellar releases, and posterior medial and lateral capsulotomy. The ROM was only 15-80 degrees.

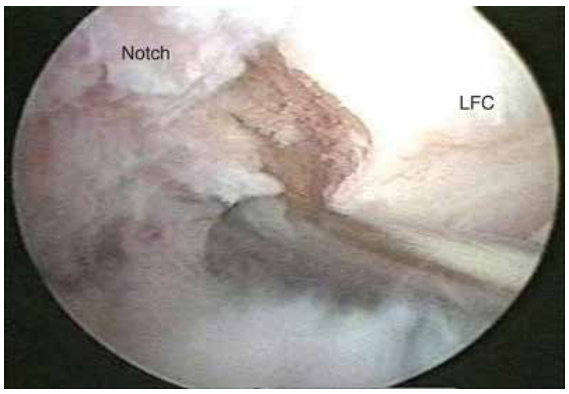

An arthroscopic lysis of adhesions, removal of scar tissue, and parapatellar releases is performed first. All scar tissue from the notch region is removed and a notchplasty done so that these tissues do not block extension.

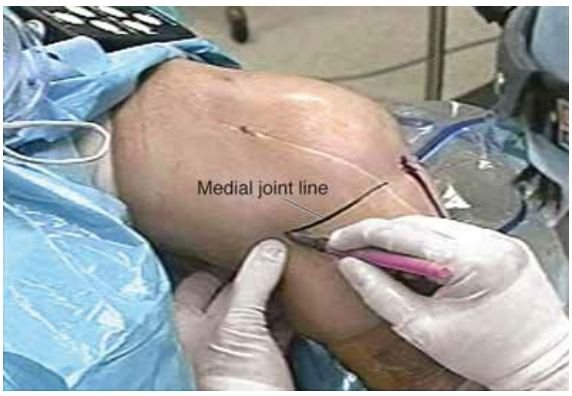

The medial joint line is marked.

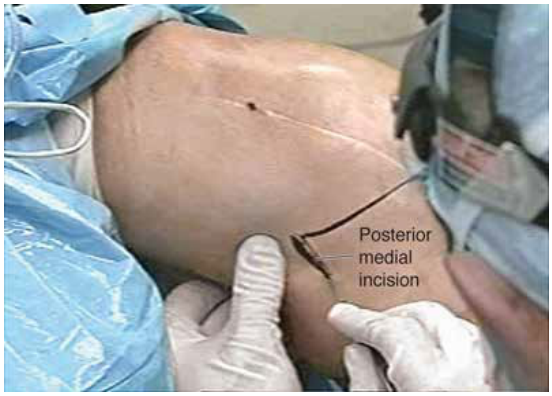

A posteromedial incision is made.

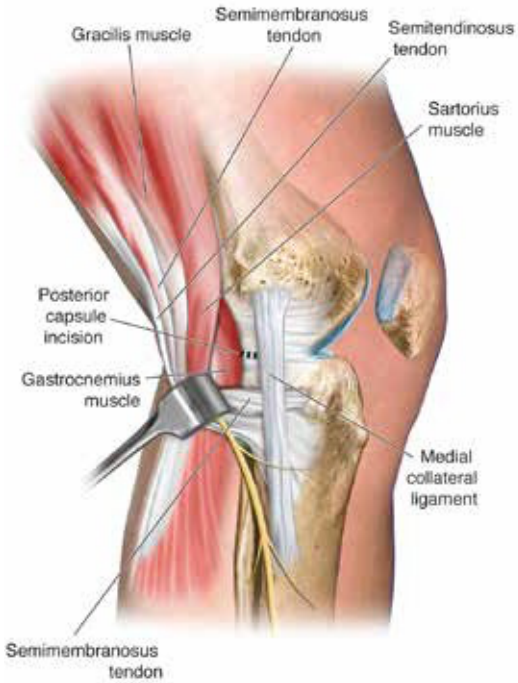

An illustration of the approach that is used, reflecting the sartorius.

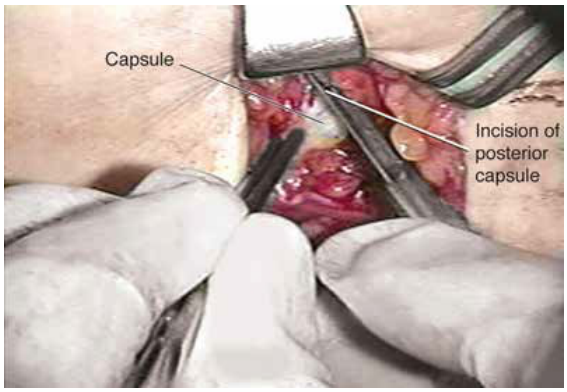

A vertical posteromedial capsulotomy is made directly behind the superficial medial collateral ligament.

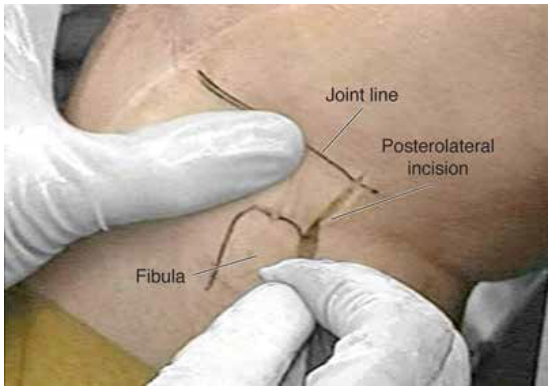

The posterolateral approach for a capsular release is performed just distal to the joint line.

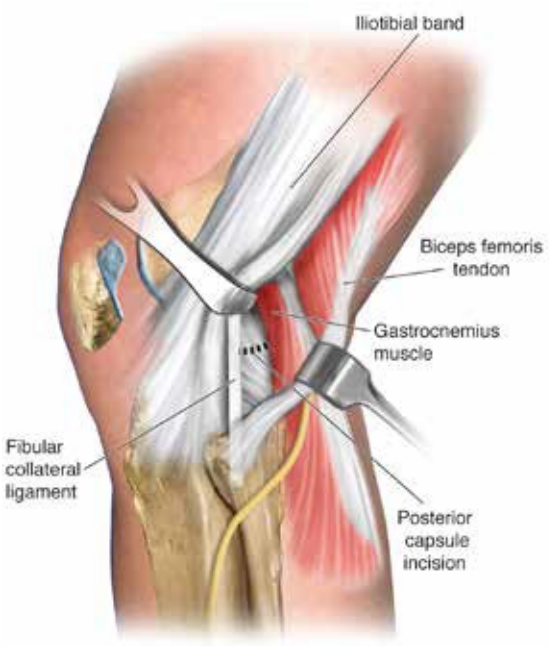

The posterolateral capsule anterior to the gastrocnemius tendon is identified.

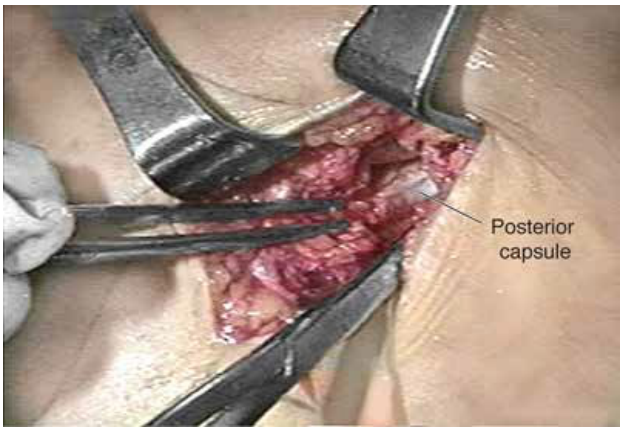

The posterolateral capsule is carefully incised under direct visualization to the edge of the lateral femoral condyle, avoiding the neurovascular structures.

A finger is placed into the posteromedial and posterolateral incisions and the central neurovascular structures are palpated. The central posterior capsule anterior to the neurovascular structures is not released. The finger palpation confirms that the capsule directly posterior to the medial and lateral femoral condyles has been incised, removing this block to extension as the knee is extended.

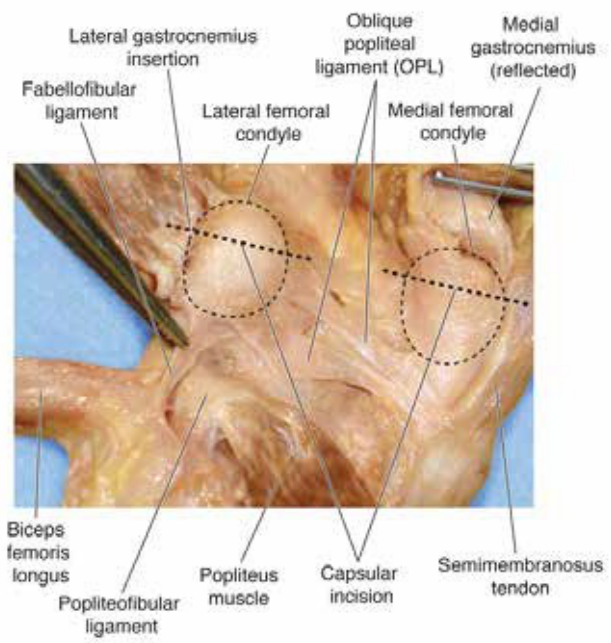

The posterior capsular releases, shown here in a cadaver specimen.

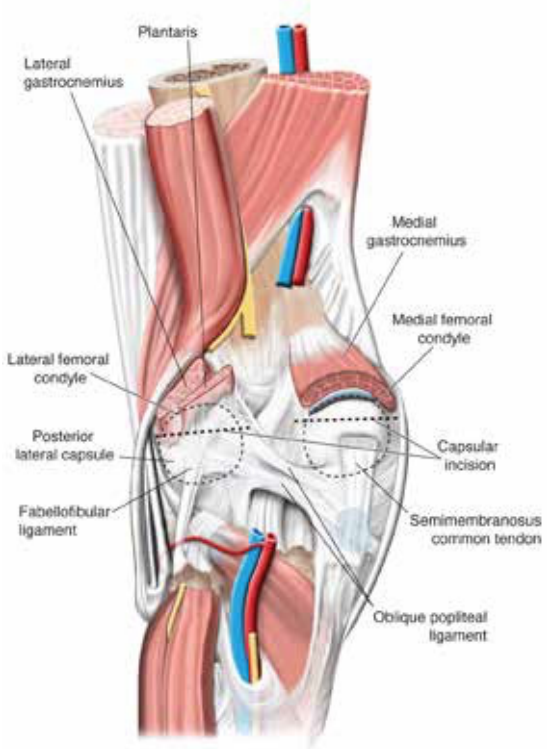

Illustration of the posterior capsular releases.

Important Comments Regarding These Operations

The operations we have described are extensive and education and discussion with the patient and family are necessary to understand the goals and potential complications. The postoperative treatment is long and formal physical therapy visits are required usually 3-5 times a week. Insurance companies need to be notified and approval for extended rehabilitation services and visits received in advance. Patients with severe arthrofibrosis treated at our Center frequently stay in town (if they reside elsewhere) for at least 4 weeks after surgery, then return home to continue the program. They frequently must return for 1-2 weeks at our Center to continue the outpatient rehabilitation program.

Every measure is taken to prevent or lessen the risk of infection that is always higher than first time surgery. Extensive use of pain modalities is required to keep the patient comfortable and be able to perform the exercises. The physical therapy staff is especially sensitive in staying optimistic to support the mental and well-being of the patient. Family members need to be supportive, attentive, and understand the treatment being delivered. It is important to understand that one in four arthrofibrotic knees may need to repeat the open surgical or arthroscopic procedure due to the early reformation of scar tissue. Commonly, the scar tissue removed the second time is much less than that encountered originally.

Other Treatment Approaches

Over the years a number of different and varying treatment approaches have been suggested, often of limited value and have not been adopted at our Arthrofibrosis Center. One treatment approach is to use knee radiation treatment to decrease the cellular response for forming scar tissue. We made the decision to not employ radiation protocols for a number of reasons. We are however constantly surveying the published literature for advances in this field. As already mentioned it is probable that newer anti-fibrotic drugs will be developed that specifically block scar tissue formation and production. The formation of altered collagen fibrous tissue that we label as scar formation will likely be blocked in the future by new drugs at the fibroblast cell level. At present there are no specific targeted drugs to specifically block scar tissue production.

Also, for the future will be to utilize newer PCR molecular testing to exclude a low-grade infectious process as the stimulus for fibrosis about the knee joint. Even though current modern bacteriology tests to culture organisms are employed in all patients, there is still the likelihood that certain patients have an infectious etiology for the arthrofibrosis that is not identified.

Ultrasound

Ultrasound is a modality or machine that uses sound waves that bounce off or penetrate tissues in the body. It consists of high frequency vibrations that enhance the flow of particles from one side of a cell membrane to the other. It is defined as sound with a frequency greater than 20,000 Hz (0.02 MHz), which is the upper limit of the range that can be registered by the human ear. Ultrasound generates a certain amount of heat that can be adjusted to target superficial or deeper structures and delivered either continuously or intermittently (pulsed).

Both 1 and 3 MHz continuous ultrasound may increase the temperature of subcutaneous tissues 4° C or more. It is the heating capabilities of ultrasound that makes it appear by some to be useful in treating arthrofibrosis by helping break up scar tissue. Continuous ultrasound has been recommended for treatment of restricted joint motion, although clinical studies proving its effectiveness are lacking. It has also been recommended for use following knee surgery to help suppress scar tissue formation but, again, this theory has not been proven in formal studies.

In general, ultrasound has therapeutic uses in treating joint injuries, pain, and swelling. It has been used to treat upper and lower extremity fractures, with some results showing that it may promote healing by inducing low-level mechanical forces at the fracture site. However, a review of 12 studies involving 622 patients failed to find a significant beneficial effect in accelerating the time for bone healing or preventing non-unions. Ultrasound has also been used to treat patellofemoral pain; however, no evidence of clinically important benefits has emerged. This treatment modality has also been used in patients with knee osteoarthritis and there appears to be a potential for reduced pain and increased function, but further research is required.

One potential problem with ultrasound is the variability in the intensity of the treatment in terms of total output power and radiating area between machines from different manufacturers. This variability is almost certain to affect the results of treatment of the same disorder between studies and could lead to false conclusions. Authors have recommended improved methods for manufacturing the devices to reduce the variability.

Extracorporeal Shockwave Therapy

Extracorporeal shock wave therapy uses sound waves of very high frequency delivered to a single focused area. The goal is to dissolve unwanted structures such as kidney stones and bone spurs. This treatment modality has been used to treat chronic plantar fasciitis, chronic lateral epicondylitis, rotator cuff tendinosus, delayed unions/nonunions, and heel spurs. It is also been used to treat acute fractures of the tibia and femur and chronic nonunion of long bone fractures. Thus far, there have been no reports regarding the use of this therapy for knee arthrofibrosis.

Inflammatory Diet

Many dieticians and naturopathic doctors are enthusiastic regarding the consumption of anti-inflammatory foods to reduce the chronic inflammation that many individuals suffer, including osteoarthritis, diabetes, fibromyalgia, and rheumatoid arthritis. These foods include very lean meats, antioxidant-rich fruits and vegetables (bright or deep-hued in color), high-fiber grains, brown rice, fish, nuts, and legumes. Other beneficial foods are the spices turmeric, ginger, cinnamon, curry; tart cherries, green tea, and dark chocolate (small amounts). Foods to avoid include red meat, pork, poultry, eggs, butter, processed foods that contain trans-fatty acids, cakes, cookies, white bread, potatoes, and white rice.

There have been several books written on inflammatory diets for those who are interested in receiving more information. Unfortunately, to date no studies have been conducted on the potential effectiveness of an inflammatory diet helping patients with knee arthrofibrosis.

Stem Cell, Platelet Rich Plasma (PRP) and Other Types of Knee Injections

We are aware of investigational studies using so called "stem cell" injections for the treatment of arthrofibrosis and other knee conditions. First, it is important for patients to know that the FDA has come out very strongly to inform the public that "stem cell" products do not contain a sufficient number of stem cells (often just a few) to have any effect and false advertising on these products may be subject to prosecution. Second, there are umbilical and placenta products that have been removed from the market as unsafe and a potential risk of infection and our Institute and doctors made the decision to avoid umbilical and allograft products.

The two products that have been investigated from an Orthopaedic standpoint at responsible institutions are platelet rich plasma (PRP) and bone marrow aspirate concentrate (BMAC) that are autogenous meaning obtained from the patient. There is insufficient clinical published data and studies to know if PRP or BMAC injections decrease inflammation and are efficacious in the treatment of arthrofibrosis and therefore their use at present is investigational. This is an important area for future study. A PRP injection (low leucocytes) does contain potent naturally occurring chemicals that may have anti-fibrotic effects. However, this remains speculative and investigational at present with no proven clinical studies for patient recommendations.

In summary, it is important to decrease tissue inflammation that plays a strong role as a stimulus for abnormal collagen synthesis and scar tissue production. Recent published studies show there are major changes in gene sequencing in patients knee scar and increases in biomarkers (Transforming Growth Factor -beta receptor 1, TGFBRI) and current investigations are focusing on drugs that will block these effects, although this may be some time in the future. Accordingly, the primary medical treatment employed is to use medications (Cox 2 Inhibitors, steroid medications) to down-regulate the inflammatory cascade and decrease myofibroblast proliferation and excess collagen scar tissue production. It is important that side effects from these medications be avoided and patients with cardiovascular disease or history of stroke or ischemia are at increased risk with NSAIDs.

PATIENT CONSULTATION ON KNEE ARTHROFIBROSIS

There are important patient education issues and treatment decisions to be made when this unfortunate and somewhat devasting knee condition that may occur after knee injury or surgery. The Cincinnati Sports Medicine and Orthopedic Center and the Noyes Knee Institute have had extensive experience with knee arthrofibrosis for over three decades.

The treatment decisions and protocols have been published in many forms and are used worldwide. The eBook on Arthrofibrosis is very informative and patients are requested to obtain this reference. The purpose of this information sheet is to summarize the patient consultation and the decisions and treatment approaches discussed.

1. Knee Arthrofibrosis represents very dense scar tissue that occurs in and about nearly all knee structures in the front, sides and back of the knee joint and dense scar tissue within the knee joint. Based on the examination, the locations of the Arthrofibrosis will be explained.

2. Knee Arthrofibrosis is classified into mild --- moderate --- severe: based on the loss of knee motion and the anatomic location of scar tissue. The severity and duration of knee arthrofibrosis negatively effects the success of treatment.

3. A loss of knee flexion is due to scar tissue and shortening of knee tissues about the kneecap (patella) that becomes very tight and limits knee flexion. In addition, scar tissue forms below the patellar tendon (anterior interval), and scar tissue above the patella (suprapatellar pouch) that binds down the entire quadriceps muscle system. If surgery is considered, all of these knee areas need to be visualized and scar tissue removed.

4. When knee flexion is reduced, the quadriceps muscle shortens in a few months and then becomes a further block or resistance to knee flexion. The principle is to remove all the scar tissue (item 3) and then proceed with a gentle but persistent program in low repetitive forces to stretch out remaining scar tissue and the quadriceps muscle system. When treatment is started early, within months, it is possible to stretch out the quadriceps muscle. However, when treatment is delayed 12-18 months there may be permanent muscle shortening that continues to block knee flexion. The knee motion program to regain knee motion is referred to as the "Over-pressure" approach. This program avoids large forces that may cause further soft tissue irritation and damage that would act to stimulate the return of scar tissue. A patient is instructed in the different forms of over-pressure rehabilitation with low and gentle pressure or forces over a longer duration of time.

5. The condition of Patella Infera refers to a shortening and reduced length of the patella tendon. When this occurs, an abnormal position of the patella occurs resulting in a very low patella and often a marked loss of knee motion. There is an entirely added treatment approach that is explained if this condition has occurred.

6. A loss of knee extension is caused by shortening and contracture of capsular tissues in the back of the knee joint. There may also occur contracture of other tissues about the knee joint. When treated early within months, an over-pressure program over 4 -6 weeks may regain most of the lost extension. However, when loss of knee extension occurs for months, the contracture becomes dense and open surgical procedures are required, either by release of the scar tissue directly, or by major revision surgery.

7. It is important to individualize a treatment program for each patient on a case by case basis. There are many factors to be analyzed including the overall health of the patient, added medical conditions, and ability of a patient to undergo further knee surgery and extensive post-operative rehabilitation. Special programs such as Blood Flow Restriction Therapy (BFRT) are employed and introduced to the patient as limb muscle atrophy is often severe and unresponsive to rehabilitation.

8. With the loss of knee flexion, one approach is to perform an extensive ARTHROSCOPIC RELEASE and removal of the scar and shortened knee tissues using a radiofrequency device. This is a more ideal procedure, however only possible in mild to moderate involved knees. Each patient is evaluated to determine if this less invasive procedure would be successful.

9. When the loss of knee flexion involves a marked contracture and shortening of knee tissues, and in particular about the kneecap, it is necessary to perform an OPEN RELEASE and removal of scar tissue, and performing a "Z-plasty" lengthening of shortened tissues. This allows for the tissues to have a normal length to function and not block knee motion. This open procedure is still performed in a minimal invasive approach to avoid undue knee trauma and dissection.

10. After the surgical release of the scar tissue and lengthening of tissues, it is necessary to enter into a very comprehensive post-operative rehabilitation program over 12 weeks. The scar tissue will often begin to return in the second week after surgery. During this time over-pressure approaches to maintain knee flexion are employed and demonstrated to the patient. It is necessary for treatment in the outpatient clinic with the specialized physical therapist 2-3 times a week and also preform the stretching exercises 6 times a day at home. Patients need at least 20 or more therapy visits and need to coordinate this with their insurance provider. Patients from out of town make special arrangements to stay in Cincinnati during some of the weeks after surgery and our staff assists in recommendations for housing. An experienced PT group in the patient's hometown is also involved for when the patient returns home following our rehabilitation protocol.

11. It is often required to prescribe special medications to decrease knee inflammation and swelling after surgery as this is one of the major factors for the return of knee scar tissue and an unsuccessful result. Be sure and let the surgical team know of any medical contraindications to any medicine prescribed. A short course of steroids (prednisone or DosePak) is often used if the patient does not have diabetics or other contraindications. All medicines have the potential for side effects. A special medicine called Anakinra may be prescribed that is highly beneficial to block the return of scar tissues, and insurance may or may not cover the cost (approx. $1700). There are new investigational programs on the use of autogenous platelet-plasma
knee injections designed to decrease knee inflammation and decrease the return of scar tissue.

12. Knee Arthrofibrosis is a very severe complication, and the treatment programs may not be successful in restoring knee motion. The results of these programs really depend on the patient's response to removing the scar tissue and stretching out remaining soft tissues that are limiting knee motion and to avoiding the return of the scar tissue. All of these factors are difficult to predict before surgery and therefore it is not really possible to know a patient's success rate. In our experience, approximately 50% of patients are pleased with the results, and about 25% are improved however do not achieve the results they hoped for as some scar tissue returns and still produces symptoms. The remaining 25% have a return of scar tissue, limitations in knee motion and the program is not successful despite all attempts of the patient and treatment team. This is most unfortunate and usually leads to further surgery and with a Knee Replacement, a knee revision procedure and down-sizing of knee components and other open approaches. Patients are accepted into the soft tissue surgical approach to avoid a major open revision that is much more invasive, realizing overall success of this approach is not guaranteed.

13. One of the most serious complications from any surgery is infection and extensive precautions and major antibiotics, wound cleansing procedures, and other approaches are performed at surgery. Even so, the overall infection rate of knee replacement surgery is one to two percent and may be higher when repeat operative procedures are performed. When an infection occurs with a total knee replacement, a revision specialist performs surgery to remove the knee implant, install a temporary spacer to allow knee motion, and after antibiotic treatment over a few months the knee implant is replaced in a second operation. The success of these procedures to cure the infection varies between patients and is a separate matter. Because of the possibility of infection, even though small, every patient needs to consider living with the loss of knee motion and accepting their condition as permanent. Patients undergo the soft tissue operations described when their quality of life is markedly affected, and the patient refuses to accept the arthrofibrosis loss of motion and overall knee impairment.

14. As a positive summary to the above issues, the Noyes Knee Institute has a highly experienced team of experts and our Institute has received multiple recommendations and awards for the excellence of the programs. Most important, is the compassionate care and understanding provided for patients going thru this difficult treatment program. We are pleased to provide patient references and answer all questions. We remain hopeful that our patients respond to our treatment approaches to improve their quality of life and ability to carry on their life goals.

Patellar Infera: Recognition, Prevention, Treatment

Recognition

The term patella infera (or baja) refers to a condition in which the patellar tendon shortens and the patella is pulled downwards on the tibia, shown in the x-rays below.

X-rays of a 42-year old patient who sustained a patellar fracture and required 2 screws to fix the damage. She came to our Center 7 months later with a severe patella infera. The opposite, normal knee is shown on the right. You can see that the patella on the left is much lower, closer to the tibia.

Patella infera may occur due to many reasons, such as poor rehabilitation following knee surgery; a fracture in the femur, tibial plateau, or patella; rupture of the quadriceps muscle; or as a result of reflex sympathetic dystrophy or complex regional pain syndrome. It is secondary to contracture of the tissues that surround the patella and severe quadriceps weakness. Patella infera may be successfully treated if diagnosed early, before the condition becomes permanent. Early signs and symptoms of patella infera are:

- Pain with quadriceps contraction
- Poor, inadequate contraction
- Soft tissue swelling, edema
- Joint stiffness, limited motion
- Decreased patellar mobility, peripatellar contracture
- Decreased tension in the patellar tendon

Serial lateral x-rays should be taken to detect any decrease in patellar height for patients demonstrating limited patellar mobility as early as 4-6 weeks postoperative. These x-rays are also indicated in patients who demonstrate an early arthrofibrotic response, limitation of knee motion, or severe quadriceps atrophy. We previously showed the illustration for measuring height of the patella (How is Knee Arthrofibrosis Diagnosed?).

The good news is that patella infera can be successfully resolved if detected and treated early. The bad news is that, if this complication is not treated early, the patellar tendon will shorten and the condition may become permanent, leading to eventual severe arthritis in the patellofemoral joint.

Prevention

As with arthrofibrosis, the best treatment of this problem is prevention through a comprehensive rehabilitation program. This is especially true for patients about to undergo any knee surgery.

The patient should be instructed before surgery on the importance of achieving a voluntary quadriceps contraction (ability to tighten the muscle) as soon as possible after surgery, which is expected to occur by the second postoperative day. Immediate knee motion and patellar mobilization exercises should begin the day following surgery. The use of electrical muscle stimulation and biofeedback are important adjuncts to the rehabilitation program in the first few weeks after surgery.

Patients who fail to achieve 0-90 degrees of knee motion by the 7th day after surgery should be placed into the overpressure program we have described in this eBook. Patellar mobility should be assessed weekly by the therapist to detect any early contracture of the tissues that surround the patella. Any suspicion of a problem or detection of an early arthrofibrotic response to surgery warrants examination by the surgeon and lateral x-rays as previously described.

Treating Early Patella Infera

If a transient (or early) patella infera condition is detected, it can usually be resolved through supervised rehabilitation and an arthroscopic release of contracted tissues. Emphasis is placed on regaining normal knee motion, patellar mobility, and quadriceps muscle strength.

Joint effusions are aspirated as required to promote full voluntary quadriceps contraction.

Knee motion and patellar mobilization exercises are performed 4-6 times daily.

Electrical muscle stimulation and biofeedback are used to promote strong quadriceps contractions.

Strenuous exercises are avoided that might aggravate the inflammatory condition.

Oral corticosteroids may be considered if non-steroidal anti-inflammatory medications are not successful in resolving joint swelling.

If an early patella infera goes unrecognized or untreated for a few months, it then becomes established and is much more difficult to treat. Frequently, there is a dense band of scar tissue that has formed between the patella and tibia (infrapatellar contracture) that is identified by an MRI and requires early arthroscopic release and debridement. Unfortunately, if the patellar height and tendon shortening is 25-50%, it is usually permanent even after arthroscopic surgery. Early diagnosis and treatment are therefore imperative.

Treating Chronic Patella Infera

Patients with chronic, established patella infera require more extensive treatment methods in an attempt to treat the established contractures. Established patella infera results from a series of events. You can see how arthrofibrosis comes into the picture in the development of this disastrous complication:

Quadriceps weakness. Initially inhibited by the pain, the quadriceps becomes weak and wasted.

Contracted peripatellar retinacular tissue. As part of the capsular thickening, the fibrous structures at the sides of the patella become thickened and contracted.

Chronic patellar entrapment. The patella becomes immobile, and unable to be moved from side-to-side or up and down.

Quadriceps contracture. In response to disuse, the quadriceps tendon above the patella contracts.

Fibrosis of the patellar tendon. Below the patella, abnormal fibrous tissue develops in the patellar tendon, and the deep and superficial infrapatellar bursae.

Scarring of the infrapatellar fat pad. The process extends to the fat pad.

Chondrification and calcification of the capsule, fat pad and surrounding tissues. Fibrous tissue starts to change even further, turning partly into cartilage and calcifying like bone.

Infrapatellar contracture syndrome. The whole block of tissues below the patella contracts.

Permanent shortening of the patellar tendon. The fibrous tissue in the patellar tendon contracts permanently.

Patellar infera. The patella is pulled downwards towards the tibia.

Patellofemoral arthritis. The articular cartilage joint surfaces between patella and underlying groove of the femur become severely damaged.

The patella infera condition may be classified into one of two types based on the damage to the articular cartilage. Several years ago, we described a group of patients who had severe damage to the undersurface of the

kneecap and in these cases, the surgical option of lengthening the patellar tendon to correct the position of the patella was not of benefit. In these patients, we remove the scar tissue and restore the retinaculum to help alleviate some of the pain, but they realize they are gradually going to wear out their patella and require a knee replacement.

There is a second form of patella infera where a young patient has lost (for example) 50% or more of the length of the tendon and still has relatively normal articular cartilage. Here, the goal is to protect the joint and restore the patella to a normal position. In these rare cases, there are two ways to accomplish this goal. One procedure is referred to as a DeLee osteotomy – the tibial tubercle is removed and advanced proximally. The second option that we prefer is to lengthen the patella tendon – which is a little bit more difficult to do, but is the best way to restore the patella to its normal position because the tibial tubercle is not moved. On occasion, lengthening of the patellar tendon is performed which allows an eventual total joint replacement to be more functional with a more normal positioning of the patella.

Before any surgery is considered, the patient must re-establish quadriceps muscle function to avoid a quadriceps shutdown after the surgical procedure. Then, the contracted and scarred tissues are removed either by arthroscopic or open surgery. This is followed by a number of months of intensive supervised physical therapy. This protocol helps many patients, especially those who are willing to live with some functional limitations, understanding that an eventual knee arthroplasty procedure may be required.

For those select cases where patellar tendon lengthening is indicated, the procedure is done at this point. If possible, the patient's patellar tendon undergoes a z-plasty lengthening and then is augmented with a graft taken from the patient's semitendinosus and gracilis tendons.

In the worst cases, the patellar tendon is essentially non-existent and a second graft (usually an allograft) must be used along with a graft taken from the patient's semitendinosus-gracilis to create a new tendon. These major operative procedures require at least 6 months of rehabilitation to obtain the best recovery possible.

Complex Regional Pain Syndrome (CRPS)

What is it?

Complex Regional Pain Syndrome (CRPS) is an uncommon form of chronic pain that usually follows an injury or surgery. The pain frequently affects an arm or leg and is out of proportion to the severity of the injury or surgery. It is associated with changes in skin color, temperature, sweating, edema (swelling) and ROM. The patient may experience pain with just light touch, such as a bed sheet on their leg. The pain may be burning or shooting in nature or deep, constant, and aching. This is a real problem because it often causes a delay in diagnosis as physicians may believe the patient is either seeking recreational drugs, has a psychological disturbance, or some other secondary gain issues.

The Human Nervous System

To understand CRPS, a basic understanding of the human nervous system and function is required. This is because this syndrome occurs due to high levels of nerve impulses that are sent to an affected area.

The nervous system consists of the central nervous system (CNS, brain and spinal cord) and the peripheral nervous system (PNS). CRPS may occur as a result of dysfunction of either the CNS or PNS.

The PNS contains nerves that connect the CNS to every part of the body. The CNS receives and interprets signals from the PNS and also sends signals to it. There are 43 main nerves that branch off the CNS to the PNS.

The PNS is divided into two parts: the somatic nervous system and the autonomic nervous system.

The somatic nervous system consists of fibres that are responsible for the voluntary movements of our body, while the autonomic nervous system incorporates movements and essential functions that are done involuntarily (breathing, heartbeat, etc).

The autonomic nervous system has two divisions that keep each other in check: the sympathetic and parasympathetic divisions.

The sympathetic nervous system is responsible for what is called the fight-or-flight response due to the response of two receptors; alpha and beta. When the alpha-receptors are stimulated, the body responds with elevated heart rate and blood pressure, piloerection ("goose bumps"), and skin vasoconstriction (pale skin). When the beta-receptors are stimulated, the body responds with increased heart rate, muscle vasodilation (increase in muscle size), and bronchial dilation (increased airflow to the lungs). The autonomic nervous system may go haywire and cause the wide variety of symptoms and complaints.

CRPS Types I and II

By definition, the previously named disease reflex sympathetic dystrophy (RSD) is now referred to as CRPS Type I, and the formerly named causalgias are incorporated into the definition of CRPS Type II. The International Association for the Study of Pain established the initial definition of CRPS to help eliminate confusion. The pain generator is termed either sympathetically maintained pain (SMP) or sympathetically independent pain (SIP), depending on whether or not the sympathetic nervous system is involved.

Both CRPS Types I and II have components of SMP and SIP. In fact, both SMP and SIP will frequently exist in each patient to varying degrees. There are periods when the nerve transmissions from the sympathetic nervous system will be interpreted by the body as pain. When this occurs, the normal signals to increase heart rate and blood pressure in response to fight or flight conditions not only affect the sympathetic nervous system, but also cause pain. This source of pain is SMP. All other pain associated with CRPS is SIP.

Potential Causes of CRPS

There have been several hypotheses described for the cause of CRPS and we will discuss these briefly next. One hypothesis is that a pathologic interaction occurs between the somatic nervous system and the autonomic nervous system. Normally, these two systems do not directly interact. However, when a pathologic interaction does take place, it occurs at a newly created abnormal synapse called an ephapse. An ephapse may take place in either the PNS or the CNS. The ephapse causes a type of short-circuit to occur between the somatic and autonomic nervous systems. The signals being sent from the CNS to the PNS to control heart rate and other factors are short-circuited to sensory fibers and are misinterpreted as pain signals being sent from the PNS to the CNS. The sympathetic nervous system drives the pain and, as a result, increased anxiety (which would normally increase blood pressure and heart rate) that amplifies pain.

Another theory focuses on CRPS Type II in which a specific nerve has been damaged. A neuroma forms as a result of the injury. Within this neuroma, the transected sensory nerve endings develop catecholamine sensi-

tivity through the upregulation of alpha receptors (which respond to epinephrine from the autonomic nervous system). In this manner, when the sympathetic nervous system sends signals to increase heart rate, the increased density of alpha receptors in the sensory nerve endings of the neuroma are stimulated and transmit the pathologic pain signal back to the CNS.

There is also a theory in which a similar upregulation of alpha-receptors occurs in the dorsal root ganglion. A ganglion is a compact group of nerve cells located outside the brain or spinal cord. Dorsal root ganglions, located along the vertebral column by the spine, carry signals from sensory organs to the CNS.

These theories helps to explain the increased pain patients have in physical therapy or in the clinic, as they anticipate the pain associated with an examination or treatment. This anxiety stimulates the fight-or-flight response. The catecholamines released from the sympathetic nervous system stimulate the intended targets of heart and blood vessel. However, because of the upregulation of alpha-receptors in either a neuroma or the dorsal root ganglion, they also stimulate the sensory nervous system and produce pain.

The clinical findings of light touch hypersensitivity (allodynia) and cold hypersensitivity (hyperalgesia) are believed to occur through a central sensitization model termed the Raja model. In this model, pain receptors (nociceptors) upregulate their alpha-receptors. Because the body is constantly sending sympathetic signals, these nociceptors are being constantly stimulated which reduces the CNS threshold for perceiving pain. Once again, changes occur in the dorsal root ganglion. The mechanoreceptors responsible for light touch sensation and thermoreceptors responsible for cold sensation instead produce an abnormal painful response when they stimulate the sensitized central pain neurons.

The change in regulation of alpha-receptors also explains the change in appearance of the limb over time. Initially, an increase in alpha-receptors causes excess stimulation that presents as a red, warm, and swollen limb (increased sympathetic function). Later, as the body adjusts and down-regulates the expression of alpha-receptors, the same limb will take on a blue, cool, and contracted appearance.

Diagnosis

The clinical presentation of a patient with CRPS may vary widely and this is why it can be difficult to diagnose the syndrome in its early stage. The disease has no preference regarding gender, age, or dominant extremity. The common cause is an initiating trauma to an extremity, which can be as obvious as a fracture or as minor as an ankle sprain. It can also occur in response to surgery, arthritis, and inflammatory conditions or reactions.

Despite the complexity of the definition of CRPS, the hallmark of this disease is pain out of proportion to the inciting event. Early treatment before the changes of skin color, temperature, and sweating occur provides the best chance of a favorable outcome.

Patients describe CRPS-related pain as burning and shooting, or as deep, constant, and aching. A classic finding is allodynia, or pain with light touch. Patients may be unable to tolerate pressure from bed sheets at night, clothing, and even air currents. The pain may fluctuate in intensity. Aggressive physical therapy that is painful to the patient may worsen the condition. Colder weather may also worsen CRPS.

Sympathetic dysfunction is manifested through changes in skin color, swelling, temperature changes, and cold intolerance. Classically, the limb will initially appear red, warm and dry, and progress over time to a mottled, bluish, cool and moist condition.

Patients frequently report swelling which is painful. Swelling is a prominent finding early in the course of the disease that decreases over time. Initially, the skin is edematous, but gradually changes to tight, shiny, and lacking in normal skin creases.

Many patients have a complete intolerance to cold. This finding is particularly sensitive for diagnosing SMP. Cold intolerance is often first noted in physical therapy when cryotherapy that is normally used to control swelling produces significant pain. In the office, an ice cube test may be done by applying ice to the sensitive region and determining the patient's reaction, which is often intolerable, burning pain. In the very early phase, the patient may describe a decreased cold sensation compared to the contralateral limb. In a similar manner, cold weather can precipitate a painful flare.

The natural history of sympathetic dysfunction falls into three stages; acute, dystrophic, and atrophic. These stages do not follow a specific timeline and the patient can go forward and backward through the stages over time or in response to treatment. For this reason, the staging system has little clinical usefulness other than to understand the classic progression of the disease.

The acute stage usually lasts less than 6 months. During this time, the sympathetic system is hyperactive, yielding a limb with red, warm, and dry skin.

The dystrophic stage begins after 3 to 9 months when the hyperactive sympathetic system finally diminishes to a period of decreased sympathetic activity. In this stage, the limb is cyanotic or mottled, cool and moist, with thickening of the nails and coarse hair (due to decreased blood flow to the skin).

When the dystrophic stage persists long enough to produce an overall level of atrophy in the limb, the patient enters the atrophic stage. This stage is characterized by thin, tight, shiny skin, osteoporosis from prolonged decreased weight bearing, and joint contractures from prolonged decreased range of motion.

Paravertebral sympathetic ganglion blockade is the best tool for diagnosing SMP-related CRPS and initiating treatment of CRPS. The only way to determine how much of the patient's pain is due to SMP and how much is due to SIP is to perform a sympathetic nerve block. The pain relieved is SMP, while the remaining pain is SIP. Diagnosis of CRPS based on triple phase bone scans is controversial because the test results vary based on the phase of the disease. During the acute phase of CRPS, bone scans have sensitivity and specificity rates that range from 60% to 100% and 80% to 98%, respectively.

MRI is a poor test for confirming CRPS. However, it can be useful in ruling out other possible causes of pain and allow the clinician to narrow the differential diagnosis. MRI may also be useful in identifying a possible focus for the pathology that triggered the disease.

There is no laboratory marker for CRPS. Standard x-ray films will reveal decreased cortical density of the affected extremity when compared to the contralateral limb as the disease progresses to the hystrophic and atrophic phases.

Treatment

The long-term prognosis of a patient diagnosed with CRPS is dependent upon the time span from the onset of the disease to the initiation of treatment. Ideally, treatment should begin as soon as possible, within a few weeks of the onset of the disease. Treatment often requires specialists from multiple medical disciplines. The cooperation of orthopedists, pain specialists, anesthesiologists, physical therapists, neurologists, psychologists,

and primary care physicians is required to provide the most effective care.

Physical Therapy
Physical therapy is the core treatment for CRPS and all other treatment options are performed in addition to physical and occupational therapy. The physical therapist treats pain, swelling, stiffness, weakness, and works toward restoration of limb function. The significant pain patients experience to light touch (allodynia) must be retrained to be perceived as simple touch and not pain. This is accomplished through vibration, massage, temperature contrast baths, and electrical stimulation. Muscle strengthening exercises are done as tolerated. ROM exercises are done and gait retraining is accomplished if required.

Medications
Few medications have been tested in rigorous clinical trials to treat CRPS. Of the medications listed below, only the steroids, bisphosphonates, Vitamin C, and adrenergic active drugs have been tested in randomized controlled trials. Of the remaining, some have been tested in neuropathic pain conditions such as diabetic peripheral neuropathy, some have been tested in a CRPS setting without randomization, and others simply have anecdotal support. The following types of oral medications are loosely organized by potential effectiveness:

- Corticosteroids
- Bisphosphonates
- Membrane stabilizers
- Antidepressants
- Nonsteroidal anti-inflammatories
- Calcium channel blockers
- Adrenergic active agents
- Capsaicin
- Vitamin C
- Calcitonin
- Opiates/Benzodiazepines

Paravertebral Sympathetic Chain Ganglion Blockade
Sympathetic nerve blocks may be effective because they block the sympathetic nerves next to the spine. In the Raja model we previously described, treatment by sympathetic blockade is effective due to the production of a temporary inhibition of norepinephrine release. By temporarily blocking the release of catacholamines, the sympathetic block relieves pain. By allowing the CNS to experience relief from pain, the central pain neurons may be desensitized (downregulation of alpha receptors), resulting in a long-term improvement in the painful response to light touch. As many as 10 to 15 blocks may be required for complete resolution of symptoms, but patients should experience longer and longer periods of relief between each block. We advise patients to never stop if only a few blocks have not been effective because this remains the best treatment option.

Continuous Epidural
Continuous cervical or lumbar epidural infusion may be used to treat CRPS. The drug concentration may be adjusted to allow motor function to remain intact while still blocking sympathetic and sensory input. When done along with surgery, this infusion is continued for 2 to 5 days postoperatively to minimize the chance of CRPS recurrence.

Surgical Sympathectomy
Surgical sympathectomy attempts to destroy the nerves involved in CRPS and may be considered in chronic cases of SMP. If a regional sympathetic blockade provides relief, surgical sympathectomy may be considered.

Initial pain relief may be significant, but symptoms tend to recur over the next 2 to 5 years. This is believed to happen due to incomplete surgical removal of all sympathetic innervation to the extremity.

Neuromodulation
Neuromodulation includes peripheral nerve stimulation and spinal cord stimulation. Electrodes are implanted in the epidural space in either the cervical or lumbar region. This treatment method is believed to be effective because it blocks the transmission of pain nerve fibers or causes the release of endogenous opioids. However, numerous problems and complications exist with this treatment option. Even if entirely successful, the patient will require repeat surgery for battery changes. There is also the possibility of infection, electrode displacement, and broken electrodes. The complication rate is between 30% and 64%.

Orthopaedic Surgical Procedures
Operating on a limb with active or quiescent CRPS should normally be avoided. However, if a source causing the pain can be identified, appropriate surgery is advocated to remove it. In these cases, resolution of the CRPS is unlikely to occur without surgery. When possible, the limb should be allowed to "cool down" from acute flares first. A tourniquet should be avoided because it can cause a painful flare. A continuous epidural infusion is begun before surgery to anaesthetize the skin and is continued for 2 to 5 days after surgery to help prevent a painful flare. In the postoperative period, the block is gradually reduced until it is discontinued. If during this weaning period patients begin to experience sympathetic pain, the dosage is increased until the pain is relieved and weaning begins again the following day.

Recommendations
At the time of the initial diagnosis, it is important for the patient to be educated and become a participant in their recovery. The patient may be given a Medrol Dosepak and sent to physical therapy for desensitization and active and active-assisted ROM exercises. If the patient obtains some, but incomplete relief, a second Medrol Dosepak is prescribed. If the patient does not demonstrate complete relief of their symptoms following the second dosepak, they may be prescribed Neurontin and referred to an anesthesiologist skilled with administering paravertebral ganglion blocks. Prior to a block, patients may only be able to describe a global knee pain. After the SMP is blocked, physical examination may localize to the medial joint line or over the saphenous nerve identifying possible painful foci.

We do not simply refer patients to pain management. Many pain centers do not perform paravertebral sympathetic blocks. Patients are referred only to centers skilled and experienced in treating CRPS and able to perform the paravertebral blocks necessary with the use of other medications to help resolve the condition. Multiple blocks may be required. If the condition is refractory to treatment at this point, other medications will be necessary and should be provided by a pain management specialist knowledgable in the treatment of the disease either at a local center or a major national treatment center. The mistake is to delay treatment or not persist in the acute phase to control the disease. There are websites available that offer further information and, as well, detail the necessity for psychological assistance to avoid depression (see for instance Kneeguru.com).

Acronyms and References

alpha-SMA, alpha-smooth muscle actin
ACL, anterior cruciate ligament
CNS, central nervous system
CRPS, complex regional pain syndrome
HTO, high tibial osteotomy

MCL, medial collateral ligament
MRI, magnetic resonance imaging
NSAID, nonsterodial anti-inflammatory medications
PNS, peripheral nervous system
RICE, rest, ice, elevation
ROM, range of motion
RSD, reflex sympathetic dystrophy
SMCL, superficial medial collateral ligament
SIP, sympathetically independent pain
SMP, sympathetically maintained pain
TGF-beta, transforming growth factor-beta
VLO, vastus lateralis obliquus
VMO, vastus medialis obliquus

1. Bader A. Inflammation: It's All in the Diet. Available at: www.caring.com/articles/inflammation-good-and-bad/. Accessed Jan. 11, 2013.
2. Brosseau L, Casimiro L, Welch V, et al. Therapeutic ultrasound for treating patellofemoral pain syndrome. Cochrane Database Syst Rev. 2009(1).
3. Brown CA, Toth AP, Magnussen B. Clinical benefits of intra-articular anakinra for arthrofibrosis. Orthopedics. 2010;33(12):877.
4. CDC. Normal Joint Range of Motion Study. Centers for Disease Control and Prevention. November 29, 2010. Available at: http://www.cdc.gov/ncbddd/jointROM/. Accessed Jan. 10, 2012.
5. Cosgarea AJ, DeHaven KE, Lovelock JE. The surgical treatment of arthrofibrosis of the knee. American Journal of Sports Medicine. 1994;22:184-191.
6. DeHaven KE, Cosgarea AJ, Sebastianelli WJ. Arthrofibrosis of the knee following ligament surgery. Instr Course Lect. 2003;52:369-381.
7. Desmouliere A. Factors influencing myofibroblast differentiation during wound healing and fibrosis. Cell Biol Int. 1995;19(5):471-476.
8. Griffin XL, Smith N, Parsons N, Costa ML. Ultrasound and shockwave therapy for acute fractures in adults. Cochrane Database Syst Rev. 2012;2:CD008579.
9. Group CC-MH. Ultrasound Therapy, Imaging and Shockwaves. Available at: http://www.coreconcepts.com.sg/mcr/ultrasound-therapy-imaging-and-shockwaves/. Accessed Jan. 11, 2013.
10. Harvey IA, Barry K, Kirby SP, Johnson R, Elloy MA. Factors affecting the range of movement of total knee arthroplasty. J Bone Joint Surg Br. 1993;75(6):950-955.
11. Lindenfeld TN, Bach BR, Jr., Wojtys EM. Reflex sympathetic dystrophy and pain dysfunction in the lower extremity. Instr Course Lect. 1997;46:261-268.
12. Macias-Barragan J, Sandoval-Rodriguez A, Navarro-Partida J, Armendariz-Borunda J. The multifaceted role of pirfenidone and its novel targets. Fibrogenesis Tissue Repair. 2010;3:16.
13. Magit D, Wolff A, Sutton K, Medvecky MJ. Arthrofibrosis of the knee. J Am Acad Orthop Surg. 2007;15(11):682-694.
14. Marovino T. High potency ultrasound for the treatment of connective tissue disorders. Practical Pain Management. 2010;10(8).
15. Millett PJ, Johnson B, Carlson J, Krishnan S, Steadman JR. Rehabilitation of the arthrofibrotic knee. Am J Orthop (Belle Mead NJ). 2003;32(11):531-538.
16. Millett PJ, Wickiewicz TL, Warren RF. Motion loss after ligament injuries to the knee. Part II: Prevention and treatment. American Journal of Sports Medicine. 2001;29(6):822-828.
17. Millett PJ, Wickiewicz TL, Warren RF. Motion loss after ligament injuries to the knee. Part I: causes. Am J

Sports Med. 2001;29(5):664-675.
18. Millett PJ, Williams RJ, Wickiewicz TL. Open debridement and soft tissue release as a salvage procedure for the severely arthrofibrotic knee. American Journal of Sports Medicine. 1999;27(5):552-561.
19. Najera RF. What is the Difference in an Ultrasound and Extracorporeal Shockwave Therapy? Available at: http://www.ehow.com/about_5778933_difference-_amp_-extracorporeal-shockwave-therapy_.html#ixzz1r-sQiZmWH%20http://www.ehow.com/about_5778933_difference-_amp_-extracorporeal-shockwave-therapy_.html. Accessed Jan. 11, 2013.
20. Noyes FR. Arthrofibrosis - course by Dr. Frank Noyes. Available at: http://www.kneeguru.co.uk/KNEE-notes/node/633. Accessed Jan. 9, 2012.
21. Noyes FR, Barber-Westin SD. Prevention and treatment of knee arthrofibrosis. In: Noyes FR, ed. Noyes' Knee Disorders: Surgery, Rehabilitation, Clinical Outcomes. Philadelphia: Saunders; 2009:1053-1095.
22. Noyes FR, Berrios-Torres S, Barber-Westin SD, Heckmann TP. Prevention of permanent arthrofibrosis after anterior cruciate ligament reconstruction alone or combined with associated procedures: a prospective study in 443 knees. Knee Surg Sports Traumatol Arthrosc. 2000;8(4):196-206.
23. Noyes FR, Mangine RE, Barber S. Early knee motion after open and arthroscopic anterior cruciate ligament reconstruction. Am J Sports Med. 1987;15(2):149-160.
24. Noyes FR, Mangine RE, Barber SD. The early treatment of motion complications after reconstruction of the anterior cruciate ligament. Clin Orthop Relat Res. 1992(277):217-228.
25. Noyes FR, Mayfield W, Barber-Westin SD, Albright JC, Heckmann TP. Opening wedge high tibial osteotomy: an operative technique and rehabilitation program to decrease complications and promote early union and function. Am J Sports Med. 2006;34(8):1262-1273.
26. Noyes FR, Wojtys EM. The early recognition, diagnosis and treatment of the patella infera syndrome. In: Tullos HS, ed. Instructional Course Lectures. Vol XL. Rosemont: AAOS; 1991:233-247.
27. Noyes FR, Wojtys EM, Marshall MT. The early diagnosis and treatment of developmental patella infera syndrome. Clin Orthop Relat Res. 1991(265):241-252.
28. Paulos LE, Rosenberg TD, Drawbert J, Manning J, Abbott P. Infrapatellar contracture syndrome. An unrecognized cause of knee stiffness with patella entrapment and patella infera. American Journal of Sports Medicine. 1987;15(4):331-341.
29. Rowe PJ, Myles CM, Walker C, Nutton R. Knee joint kinematics in gait and other functional activities measured using flexible electrogoniometry: how much knee motion is sufficient for normal daily life? Gait Posture. 2000;12(2):143-155.
30. Rutjes AW, Nuesch E, Sterchi R, Juni P. Therapeutic ultrasound for osteoarthritis of the knee or hip. Cochrane Database Syst Rev. 2010(1):CD003132.
31. Saxton DL, Lindenfeld T, Noyes FR. Diagnosis and treatment of complex regional pain syndrome. In: Noyes FR, ed. Noyes Knee Disorders: Surgery, Rehabilitation, Clinical Outcomes. Philadelphia: Saunders; 2009:1116-1133.
32. Scott P. Inflammation: The Hidden Time Bob Within You. Available at: http://www.caring.com/articles/hidden-bomb-inflammation. Accessed Jan. 11, 2013.
33. Shelbourne KD, Patel DV, Martini DJ. Classification and management of arthrofibrosis of the knee after anterior cruciate ligament reconstruction. American Journal of Sports Medicine. 1996;24(6):857-862.
34. Skutek M, Elsner HA, Slateva K, et al. Screening for arthrofibrosis after anterior cruciate ligament reconstruction: analysis of association with human leukocyte antigen. Arthroscopy. 2004;20(5):469-473.
35. Stanifer B. Anti-inflammatory diet tips for Rheumatoid arthritis. Available at: http://www.lifescript.com/Health/Conditions/Arthritis/Foods_that_Trigger_Rheumatoid_Arthritis_Flare-Ups.aspx?utm_source=outbrain&utm_medium=cpc&utm_campaign=Arthritis_Rheumatoid. Accessed Jan. 11, 2013.
36. Steadman JR, Dragoo JL, Hines SL, Briggs KK. Arthroscopic release for symptomatic scarring of the anterior interval of the knee. Am J Sports Med. 2008;36(9):1763-1769.
37. Stephenson JJ, Quimbo RA, Gu T. Knee-attributable medical costs and risk of re-surgery among patients

utilizing non-surgical treatment options for knee arthrofibrosis in a managed care population. Curr Med Res Opin. 2010;26(5):1109-1118.
38. Straub SJ, Johns LD, Howard SM. Variability in effective radiating area at 1 MHz affects ultrasound treatment intensity. Phys Ther. 2008;88(1):50-57.
39. Wang CJ, Liu HC, Fu TH. The effects of extracorporeal shockwave on acute high-energy long bone fractures of the lower extremity. Arch Orthop Trauma Surg. 2007;127(2):137-142.
40. Watson RS, Gouze E, Levings PP, et al. Gene delivery of TGF-beta1 induces arthrofibrosis and chondrometaplasia of synovium in vivo. Lab Invest. 2010;90(11):1615-1627.
41. Whittaker JL, Teyhen DS, Elliott JM, et al. Rehabilitative ultrasound imaging: understanding the technology and its applications. J Orthop Sports Phys Ther. 2007;37(8):434-449.
42. Yim ES, Corrado G. Ultrasound in sports medicine: relevance of emerging techniques to clinical care of athletes. Sports Med. 2012;42(8):665-680.
43. Zeichen J, van Griensven M, Albers I, Lobenhoffer P, Bosch U. Immunohistochemical localization of collagen VI in arthrofibrosis. Arch Orthop Trauma Surg. 1999;119(5-6):315-318.